



IJCRR

Section: Healthcare

A STUDY OF PROFUNDA FEMORIS ARTERY IN CADAVERS

Vaishali Prakash Ahire, Lakshmi Rajgopal

Department of Anatomy, Seth G. S. Medical College, Parel, Mumbai-400012, Maharashtra, India.

ABSTRACT

Introduction: Profunda femoris artery is the largest branch of femoral artery. It is frequently incorporated in vascular reconstructive procedures in the proximal leg.

Objectives: This study is aimed at observing the site of origin of profunda femoris artery, measuring the distance between mid-inguinal point (MIP) and the site of origin of profunda femoris artery (PFA) and studying the variations of its branches.

Materials and methods: This study was performed on one hundred and three lower limbs of properly embalmed cadavers.

Results: We found that the mean distance between MIP and the site of origin of PFA was 4.3 ± 1.13 cm on the right side and on the left side it was 4.3 ± 1.08 cm. We also found that there was a high origin of PFA in 3 cases (5.8%) on the right side and in 4 cases (7.8%) on the left side. In two lower limbs, there was bilateral higher origin of PFA. The lateral circumflex femoral artery (LCFA) was arising from the femoral artery in 9.6% of right lower limbs and 2% of left lower limbs. The medial circumflex femoral artery (MCFA) was arising from the femoral artery in 3.9% of the left lower limbs.

Conclusion: The anatomical knowledge of location of PFA and variations of its branches i.e. medial and lateral circumflex femoral arteries is important to avoid inadvertent damage to these vessels and to avoid complications during surgeries.

Key Words: Mid-inguinal point, Profunda femoris artery, Medial circumflex femoral artery, Lateral circumflex femoral artery

INTRODUCTION

Profunda femoris artery (PFA) is the largest branch of femoral artery; it is the principal supply to the muscles of the thigh. It forms the main route of collateral circulation in occlusion of femoral artery. The femoral artery at the femoral triangle is directly opened at the origin of the PFA for femoral embolectomy in lower limb arterial thromboembolism.¹ The PFA is also used for arteriography, flap surgery etc. It is frequently incorporated in vascular reconstructive procedures in the proximal leg.² In this study we measured the distance between mid-inguinal point (MIP) and the site of origin of PFA. We also observed the variations of medial circumflex femoral artery (MCFA) and lateral circumflex femoral artery (LCFA). The anatomical knowledge of location of the PFA and variations of its branches is very important for clinicians, surgeons, plastic surgeons, radiologists and interventional radiologists for performing various clinical procedures.

MATERIALS AND METHODS

One hundred and three lower limbs of 54 formalin-fixed cadavers from a tertiary care hospital were dissected carefully. In five lower limbs, the femoral artery and its branches had got cut during dissection by students and hence were not included in this study. The femoral triangle was dissected carefully. The profunda femoris artery (PFA) and its branches were identified. The anterior superior iliac spine (ASIS) and pubic symphysis (PS) were identified and marked with the help of coloured pins. The distance between ASIS and PS was measured with scale and the midpoint of this distance was taken as mid-inguinal point (MIP). The MIP was also marked with a coloured pin. The distance between MIP and the site of origin of PFA was measured (Fig. 1). We also observed any variation in the site of origin of medial and lateral circumflex femoral arteries. This study was conducted over a period of two years

Corresponding Author:

Vaishali P. Ahire, Department of Anatomy, Seth G. S. Medical College, Parel, Mumbai-400012, Maharashtra, India.

E-mail: vaishali.ahire@gmail.com

Received: 26.08.2014 **Revised:** 24.09.2014 **Accepted:** 20.10.2014

RESULTS

The profunda femoris artery (PFA) was present in all the lower limbs. The range of distance between MIP and the site of origin of PFA was 1.3 – 7.5 cm in 52 right lower limbs and 2.0 – 6.6 cm in 51 left lower limbs. The mean distance was 4.3 ± 1.13 cm on the right side and on the left side it was 4.3 ± 1.08 cm.

There was a high origin of PFA in 3 cases (5.8%) on the right side and in 4 cases (7.8%) on the left side. In two lower limbs, there was bilateral higher origin of PFA. In these cases, the mean distance between the MIP and the site of origin of PFA was 1.7 cm on the right side and it was 2.2 cm on the left side.

We found that the LCFA was arising from the femoral artery in 9.6% of right lower limbs and 2% of left lower limbs (Fig. 2). In all other cases it was arising from the PFA. The mean distance between MIP and the site of origin of LCFA from femoral artery was 4.3 cm on both the sides.

We also found that the MCFA was not arising from the femoral artery in any of the right lower limb. The MCFA was arising from the femoral artery in 3.9% of the left lower limbs (Fig. 3). The mean distance between MIP and the site of origin of MCFA from femoral artery on the left side was 2.9 cm.

DISCUSSION

Some authors have measured the distance of profunda femoris artery (PFA) from midpoint of inguinal ligament or just from inguinal ligament. In this study, we measured the distance of PFA from mid-inguinal point (MIP) and we have compared the results with similar studies in the literature.

Origin of PFA with reference to inguinal ligament

Siddharth P et al in 1985 dissected 100 lower limbs and found that the distance between the inguinal ligament and the site of origin of PFA was 4.4 cm.³

In 1990, William Chleborad et al analysed student dissections of 101 cadaver extremities (61 males and 40 females) and found that the mean distance of PFA from the inguinal ligament was 5.30 ± 1.47 cm on the right side and it was 5.31 ± 1.47 cm on the left side.⁴

Origin of PFA with reference to midpoint of inguinal ligament (Table 1)

Many authors have measured the distance of PFA from the midpoint of inguinal ligament. Those studies and their results are tabulated separately.

Origin of PFA with reference to MIP (Table 2)

Manjappa T, Prasanna LC in 2012 dissected 40 properly embalmed human cadaver specimens and found that there was absence of PFA in one case, no such variation was found in the present study.¹¹

In 2012, Mamatha H et al dissected 40 lower limbs and measured the distance of origin of PFA from MIP. The range of this distance was 3.5 – 5 cm.¹²

Suthar K, Patil D et al in 2013 described the femoral artery and its branches in detailed. They dissected 50 lower limbs and found that the distance of origin of PFA from MIP ranged in between 4 – 6 cm.¹³

In 2013, Kulkarni SP et al dissected 60 lower limbs and found that the origin of PFA was more distal than other studies.¹⁴

High origin of PFA

MB Samarawickrama et al in 2009 dissected 26 lower limbs and mentioned that in 23% of the cases the PFA was originating closer to the inguinal ligament from the lateral aspect of the femoral artery.¹

In 2011, Dixit DP, Kubavat DM et al dissected 228 lower limbs and found that in two cases, the PFA originated at a higher level i.e. between 0 – 1 cm from the midpoint of inguinal ligament.⁷

Mamatha H et al in 2012 dissected 40 lower limbs and found that the higher origin of the PFA was seen in 5% of the cases. The mean distance between MIP and the site of origin of PFA was 1.3 cm.¹²

In 2013 Sabnis AS studied the anatomical variations of the PFA. The author dissected 60 lower limbs and studied the point of origin, course and branches of PFA. The author found that in 18 lower limbs the PFA was arising just below the inguinal ligament.⁹

Suthar K, Patil D et al in 2013 dissected 50 lower limbs and found that in 23% of cases the PFA originated from lateral aspect of femoral artery. They also commented that the PFA arose laterally when it originated closer to the inguinal ligament.¹³

LCFA arising directly from the femoral artery

J Perera in 1993, dissected 62 lower limbs and found that the LCFA arose from the femoral artery in 14.6% of cases.¹⁵

In 2001, Dixit DP, Mehta LA and Kothari ML studied the origin and course of PFA and its branches. They dissected 48 lower limbs and found that the LCFA on the right side was arising from the femoral artery in 8.3% of cases. On the left side, the LCFA was arising as a common stem with PFA in 8.3% of cases.⁵

Baptist Marina et al in 2007 dissected 40 lower limbs and found that the LCFA was arising from the femoral artery in only one case (2.5%).⁶

In 2008, Uzel M, Tanyeli E, Yildirim M dissected 110 lower limbs and found that the LCFA was a branch from the femoral artery in 19.1% of cases.¹⁶

Tanvaa Tansatit et al in 2008 dissected 60 lower limbs and found that LCFA was originating from the PFA in 56.7% of cases and from the femoral artery in 43.3% of cases.¹⁷

In 2010, Prakash et al dissected 64 lower limbs and found that the LCFA was originating from femoral artery in 12 out of 64 (18.7%) extremities.²

Manjappa T, Prasanna LC in 2012 dissected 40 lower limbs and found that the LCFA on the right side was arising from the PFA in 80% of cases and from the femoral artery in 20% of cases. On the left side, it arose from the PFA in 70% of cases and from the femoral artery in 25% of cases.¹¹

Suthar K, Patil D et al, in 2013 dissected 50 lower limbs and found that the LCFA was arising from the PFA in 80% of cases and from the femoral artery in 20% of cases.¹³

MCFA arising directly from the femoral artery

J Perera in 1993 reported the variations of origin of circumflex femoral arteries dissected 62 lower limbs and found that the MCFA arose from the femoral artery in 35.4% of cases.¹⁵

Emanuel Gautier et al in 2000 dissected 24 lower limbs and found that the MCFA was originating from the femoral artery in 16.7% of cases.²¹

In 2001, Dixit DP, Mehta LA and Kothari ML studied the origin and course of PFA and its branches. They dissected 48 lower limbs and found that the MCFA on the right side was arising the femoral artery in 29.1% of cases. On the left side, the MCFA was arising from the femoral artery in 12.5% of cases.⁵

Ercan Tanyeli, Uzel M et al in 2006 dissected 100 lower limbs and found that the MCFA was a branch from the PFA in 79% of cases and from the femoral artery in 15% of cases.²²

In 2007, Baptist Marina et al dissected 40 lower limbs and found that the MCFA was arising from the femoral artery in only one case (2.5%).⁶

MB Samarawickrama et al in 2009 dissected 26 lower limbs and found that the MCFA arose from the PFA in 62% of cases whereas it originated from the femoral artery in 31% of cases.¹

In 2010, Prakash et al dissected 64 lower limbs and found that the MCFA was originating from the femoral artery in 21 out of 64 (32.8%) extremities.²

In 2012, Mamatha H et al dissected 40 lower limbs and found that the MCFA arose from the PFA in 87.5% of cases while it was originating from the femoral artery in 12.5% of cases.¹²

Danish Anwer et al in 2013 dissected 60 lower limbs and found that the MCFA was originating from the PFA in 73.3% of cases and from the femoral artery in 21.7% of cases.¹⁰

CONCLUSION

The anatomical knowledge of location of profunda femoris artery and variations of its branches i.e. medial and lateral circumflex femoral arteries is important to avoid inadvertent damage to these vessels and to avoid complications during surgeries.

ACKNOWLEDGEMENTS

Authors acknowledge the immense help received from the scholars whose articles are cited and included in references of this manuscript. The authors are also grateful to authors/ editors/ publishers of all those articles, journals and books from where the literature for this article has been reviewed and discussed. Authors would like to extend their gratitude to Dr Shubangi Parkar, Dean-in-charge, Seth G. S. Medical College and K.E.M. Hospital, Mumbai and Dr P. S. Bhuiyan, Professor & Head, Department of Anatomy, Seth G. S. Medical College, Mumbai

REFERENCES

1. Samarawickrama MB, Nanayakkara BG, Wimalagunaratna KWR, Nishantha DG, Walawage UB. "Branching pattern of the femoral artery at the femoral triangle: a cadaver study." *Galle Med J.* 2009; 14(1): 31-34.
2. Prakash, Jyoti kumari, A kumar bhardwaj, Jose BA, S kumar yadav, G singh. "Variations in the origins of the profunda femoris, medial and lateral femoral circumflex arteries: a cadaver study in the Indian population." *Rom J Morphol Embryol.* 2010; 51(1): 167-170.
3. Siddharth P, Smith NL, Robert A Mason, Fabio Giron. "Variational anatomy of the deep femoral artery." *Anat Rec.* 1985; 212(2): 206-209.
4. Chleborad W, David L Dawson. "The profunda femoris artery: variations and clinical applications." *Clin Anat.* 1990; 3(1): 33-40.
5. Dixit DP, Mehta LA, Kothari ML. "Variations in the origin and course of profunda femoris." *J Anat Soc India.* 2001; 50(1): 6-7.
6. Baptist M, Sultana F, Hussain T. Anatomical Variations; The origin of profunda femoris artery, its branches and diameter of femoral artery. *Professional Med J.* 2007; 14(3): 523-527.

7. Dixit Daksha, Dharati M Kubavat, Sureshbhai P Rathod et al. "A study of variations in the origin of profunda femoris artery and its circumflex branches." *Int J Biol Med Res.* 2011; 2(4): 1084-1089.
8. Thitilertdecha, Siriporn Rungruang et al. The origin of profunda femoris artery in Thais. *Siriraj Medical Journal.* 2012; 64: 34-36.
9. Sabnis AS. "Anatomical Variations of Profunda Femoris Artery." *Journal of Clinical Research Letters.* 2013; 4(1): 54-56.
10. Anwer Danish, Karmalkar Arun Shankar, Humbarwadi RS. "A study of variation in origin of profunda femoris artery and its branches." *Int J Biol Med Res.* 2013; 4(6): 366-368
11. Manjappa T, Prasanna LC. "Anatomical Variations of the Profunda Femoris Artery and Its Branches—A Cadaveric Study in South Indian Population." *Indian Journal of Surgery.* 2012: 1-5.
12. Mamatha H, Antony Sylvan D'souza, Jessica S, Suhani S. "A Cadaveric study on the Variations in the origin, Course and branching pattern of the Profunda Femoris Artery." *Int J Cur Res Rev.* 2012; 4(19): 137-145.
13. Suthar K, Patil D, Mehta C, Patel V et al. Cadaveric study: morphological study of branches of femoral artery in front of thigh. *CIBTech Journal of Surgery.* 2013; 2(2): 16-22
14. Kulkarni SP, Nikade V. "A Study of Branching Pattern of Femoral Artery in Femoral Triangle in Cadavers." *International journal of recent trends in science and technology.* 2013; 6(1): 53-55.
15. Perera J. "Variability of the femoral circumflex arteries." *The Ceylon Journal of Medical Sciences.* 1993; 36: 39-42
16. Uzel M, Tanyeli E, Yildirim M. "An anatomical study of the origins of the lateral circumflex femoral artery in the Turkish population." *Folia Morphol (Warsz).* 2008; 67(4): 226-230.
17. Tansatit Tanvaa, Wanidchapholoi S, Sanguansit Pasinee. "The anatomy of the lateral circumflex femoral artery in anterolateral thigh flap." *J Med Assoc Thai.* 2008; 91(9): 1404-09.
18. Mariano del Sol, Iván Suazo Galdames, Bélgica Vasquez. "The Circumflex Femoral Arteries in the Femoral Triangle." *Int J Morphol.* 2011; 29(2): 644-649.
19. Sinkeet SR, Ogeng'o JA, Elbusaidy H et al. "Variant origin of the lateral circumflex femoral artery in a black Kenyan population." *Folia Morphol (Warsz).* 2012; 71(1): 15-18.
20. Clarke SM, Colborn GL. "The medial femoral circumflex artery: Its clinical anatomy and nomenclature." *Clin Anat.* 1993; 6(2): 94-105.
21. Gautier E, Katharine Ganz, Nathalie Krügel, Thomas Gill, Reinhold Ganz. "Anatomy of the medial femoral circumflex artery and its surgical implications." *J Bone Joint Surg.* 2000; 82(5): 679-683.
22. Tanyeli E, Uzel M, Yildirim M, Celik HH. "An anatomical study of the origins of the medial circumflex femoral artery in the Turkish population." *Folia morphol-warszawa-english edition.* 2006; 65(3): 209-212.
23. Nanad lalovik, Milos Malis et al. Origin of the medial circumflex femoral artery – a cadaver study. *Med Glas (Zemica).* 2013; 10(2): 198–202.
24. BH Shiny Vinila, D Suseelamma, NS Sridevi, N Gayatri, M Sangeeta. "A study on the origins of medial circumflex femoral artery." *IOSR Journal of Dental and Medical Sciences.* 2013; 4(5): 28-31.

TABLE 1: Mean Distance between the Midpoint of Inguinal

Authors (Year of Study)	Ligament and the Site of Origin of PFA	
	Mean Distance Between the Midpoint of Inguinal Ligament And The Site of Origin of PFA (in cm)	
	Right	Left
Dixit DP et al (2001)	4.75	4.75
Baptist M et al (2007)	3.0 – 4.0	3.0 – 4.0
MB Samarawickrama et al (2009)	5.5	4.5
Prakash et al (2010)	4.2	4.2
Dixit DP, Kubavat DM et al (2011)	3.1 – 4.0	4.1 – 5.0
Thitilertdecha et al (2012)	3.6	3.3
Sabnis AS (2013)	3.2	3.2
Danish Anwer et al (2013)	3.7	3.7

TABLE 2: Mean Distance between Mip and the Site of Origin of PFA

Authors (Year of Study)	Mean Distance between Mip and the Site of Origin of PFA (in cm)	
	Right	Left
Manjappa T, Prasanna LC (2012)	3.56	3.19
Mamatha H et al (2012)	3.9	3.9
Suthar K, Patil D et al (2013)	4.8	4.4
Kulkarni SP et al (2013)	3.7	3.7
Present study (2013)	4.3 ± 1.13	4.3 ± 1.08

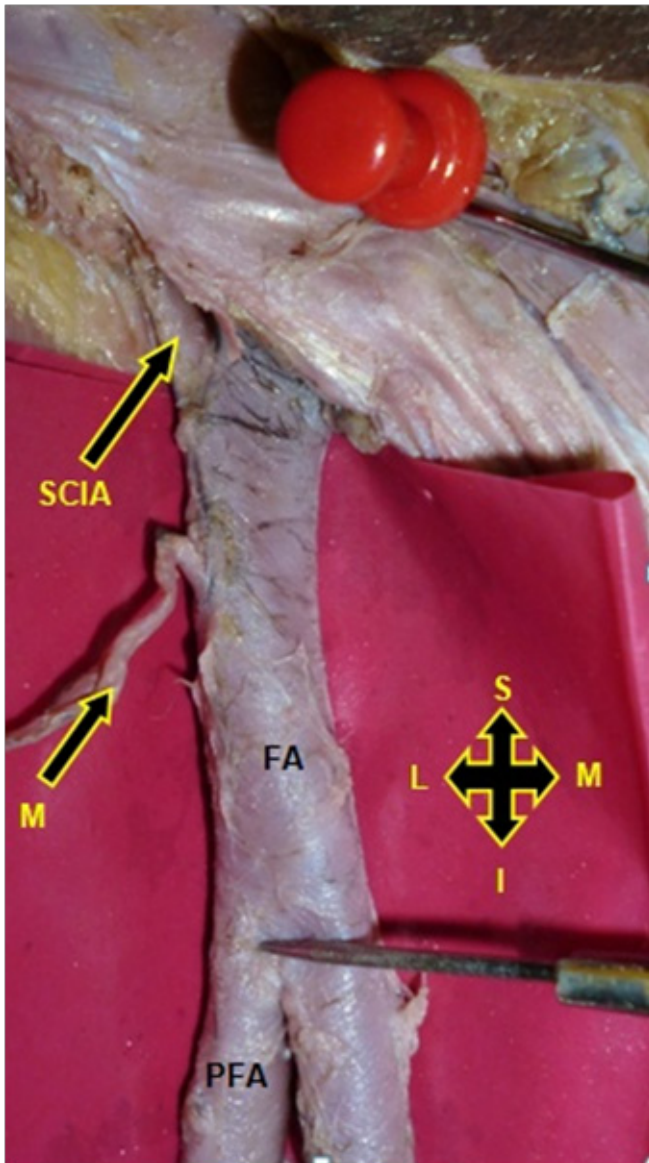


Figure 1: Measurement of the distance between the mid-inguinal point (MIP) (red pin) and the site of origin of profunda femoris artery (PFA) [FA – Femoral artery, SCIA – Superficial circumflex iliac artery, M – Branch]

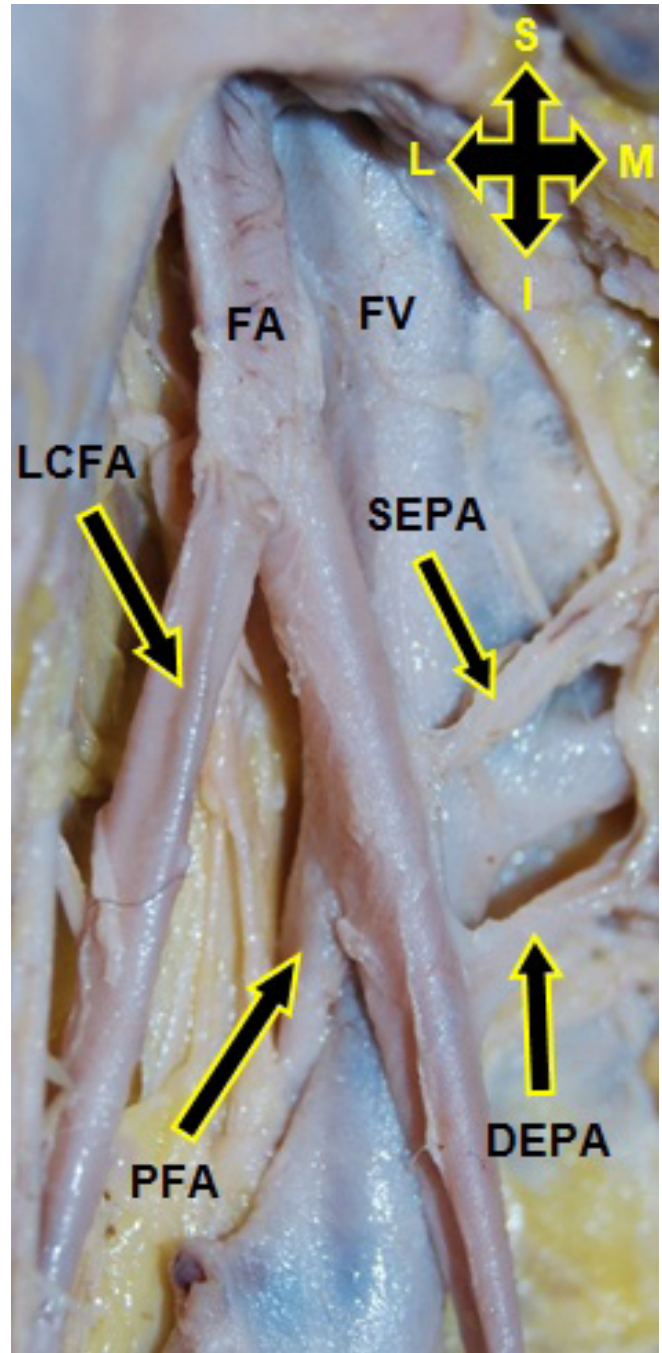


Figure 2: Lateral circumflex femoral artery (LCFA) arising directly from the femoral artery (FA) [PFA – Profunda femoris artery, SEPA – superficial external pudendal artery, DEPA – Deep external pudendal artery, FV – Femoral vein]

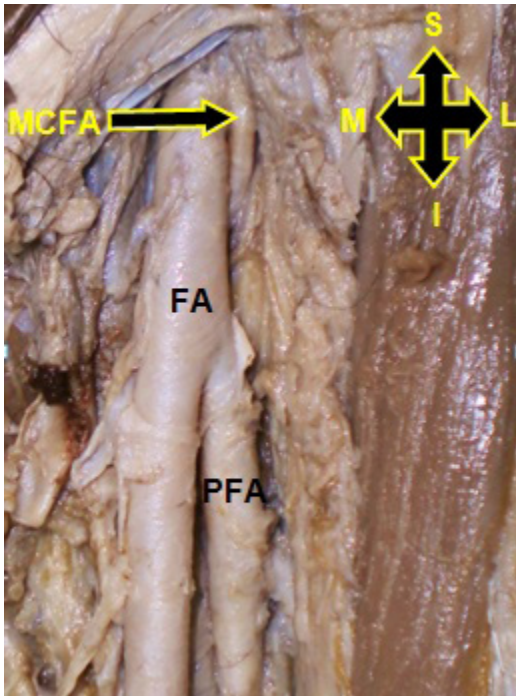


Figure 3: Medial circumflex femoral artery (MCFA) arising directly from the femoral artery (FA) (lateral aspect) [PFA- Profunda femoris artery]