



# A CASE OF HIGH GRADE MUCOEPIDERMOID CARCINOMA OF MAXILLARY SINUS

**Bindu Channabasappa, Satish Kumaran, Anuradha Navaneetham, Vijay Jain, Lalitha Thambaiah**

Department of Oral and Maxillofacial Surgery, M R Ambedkar Dental College, Bangalore, KA, India.

## ABSTRACT

Salivary gland carcinomas are rare and clinically diverse group of neoplasm among which mucoepidermoid carcinoma comprises approximately 10-15% of all salivary gland neoplasm. These malignancies are diagnosed generally at a later date during the course of the disease as they are mostly asymptomatic in nature and become symptomatic in the later stages of the disease process. We report a case of high grade mucoepidermoid carcinoma of the maxillary sinus in a 78 year old male patient in which the tumour perforated the skin on the medial aspect of the infraorbital region before the patient underwent surgery.

**Key Words:** Salivary gland carcinomas, Neoplasm, Mucoepidermoid carcinoma

## INTRODUCTION

Mucoepidermoid carcinoma (MEC) comprises approximately 10-15% of all salivary gland neoplasms and about 30% of salivary malignancies. According to description by Stewart et al salivary gland duct, composed of several type of cell types (mucous secreting, basoid, intermediate and epidermoid) represent the histological origin of Mucoepidermoid carcinoma. The tumour is well known to display a widely diverse biologic behaviour and a variable clinical manifestation which seems to correlate with tumour stage and grade.

Maxillary sinus malignant tumours are relatively uncommon malignancies and can include several histological types such as squamous cell carcinoma, adenocarcinoma, lymphoma and metastatic tumours<sup>1</sup>. Mucoepidermoid carcinoma was first reported by Alexander et al in 1974 to describe specific tumours of the salivary glands. Mucoepidermoid carcinoma accounts for 13% of all malignancies occurring in the maxillary sinus<sup>2,3</sup>. We report a case of aggressive mucoepidermoid carcinoma of the maxillary sinus in a 78 year old male patient.

## CASE HISTORY

A 78 year old male patient was referred to the department of Oral and Maxillofacial Surgery from the depart-

ment of Oral medicine and Radiology for extraction of upper right maxillary posterior teeth which were associated with mild swelling and pain on right side of the face (Figure1). On examination the swelling extended from the infraorbital region to lower border of the mandible and from the ala of the nose to the tragus. Intraorally 15, 16 and 17 were tender on percussion. Extraction of 15, 16 and 17 was done under local anaesthesia and patient was prescribed a course of antibiotics. One week following extraction patient reported back with pain and swelling in the region of extraction. On examination intraorally a mild proliferation of the soft tissue was present in the region of extraction which was reddish in colour; on palpation the growth was tender (Figure2). Patient was prescribed a course of antibiotics to rule out infection of the socket. One week later patient reported back with pain, on examination intraorally the soft tissue proliferation had slightly increased in size. An orthopantomograph was taken to rule out any associated pathologies of the sinus. Orthopantomograph showed complete radioopacity of the right maxillary sinus. A provisional diagnosis of squamous cell carcinoma of the right maxillary sinus was made and an incisional biopsy was done and the patient was advised to get a Computed tomography scan to get a complete picture of the lesion involving the maxillary sinus. Axial section of the CT scan showed complete obliteration of the maxillary sinus by a mass (Figure3). Gross specimen was soft in consistency and

Corresponding Author:

Bindu Channabasappa, Department of Oral and Maxillofacial Surgery, M R Ambedkar Dental College, Bangalore, KA, India.

E-mail: aubidmalik@rediffmail.com

**Received:** 02.09.2014 **Revised:** 29.09.2014 **Accepted:** 23.10.2014

pale brown in colour measuring 1.5×0.5cms. Histological examination of haematoxylin and eosin stained section showed a high grade mucoepidermoid carcinoma showing intracystic component with numerous mitosis. Atypical epidermoid cells and scanty mucinous cell component was seen (Figure 4). By the time the tumour was diagnosed and the patient was taken up for surgery the tumour perforated the skin and appeared in the medial angle of the eye.

## DISCUSSION

Malignancies of the nasal cavity and paranasal sinuses represent only 3-5% of all head and neck carcinomas<sup>1,3,5</sup>. The maxillary sinus is the most common paranasal sinus affected representing approximately 70% of the cases<sup>1,3,5</sup> with squamous cell carcinoma being the most common histologic type<sup>5,6,7</sup>. Maxillary sinus non Squamous cell carcinoma's include glandular carcinomas and undifferentiated carcinomas. In non Squamous cell carcinoma's of the maxillary sinus mucoepidermoid carcinoma comprises 5-10% of all salivary gland neoplasms and accounts for 13% of all malignancies occurring in maxillary sinus<sup>3</sup>. Mucoepidermoid carcinoma is a malignant epithelial neoplasm composed of both mucous secreting and epidermoid type cells in varying proportions. It was first studied and described as a separate entity by Stewart et al in 1945<sup>8</sup>. After systematic review of its histology and degree of differentiation the World Health Organisation classification in 1991 recommended that the term "mucoepidermoid tumour" is changed to "mucoepidermoid carcinoma". Maxillary sinus non -Squamous cell carcinoma's mainly affecting the adults with a female predilection<sup>2</sup>. Maxillary sinus Mucoepidermoid carcinoma's present as a long lasting asymptomatic tumour as they have a longer complaint interval and fewer symptoms reported by the affected patients. Our patient also reported with a dull pain in the right maxillary sinus region. Traditionally Mucoepidermoid carcinoma's are histologically classified as low and high grade based on the relative proportion of the cell types<sup>9</sup>. A three tiered grading scheme has replaced the previous classification, incorporating the third intermediate grade which essentially resembles with low rather than the high grade lesions. Surgery is the treatment of choice for maxillary sinus carcinomas prognosis is better for patients managed by surgery than for patients treated using Radio therapy and/ or chemotherapy alone. Maxillary sinus malignancies are very difficult tumours to treat and traditionally have been associated with poor prognosis. One reason for this poor prognosis is the close anatomic proximity to vital structures as the skull base, brain, orbit and carotid artery<sup>10</sup>. This complex location makes the complete resection of the tumour almost impossible. Treatment of maxillary sinus carcinomas with conservative surgery combined with Radiotherapy and regional chemotherapy

showed an overall 5 year survival for mucoepidermoid carcinoma<sup>2,6</sup>.

## CONCLUSION

Mucoepidermoid carcinoma of the maxillary sinus is a rare entity. Management of such tumours in the maxillary sinus has poor prognosis as the diagnosis is made late during the course of the disease as it is a slow growing tumour and due to its proximity to the important vital structures.

## ACKNOWLEDGEMENT

Author acknowledges the immense help received from the scholars whose articles are cited and included in references of this manuscript. The authors are also grateful to author/editors/publishers of all those articles, journals and books from where the literature for this article has been reviewed and discussed.

## REFERENCES

- Alexander D Rapidis, Nikolaos Givalos, Harikila Gakiopoulou et al Mucoepidermoid carcinoma of the salivary glands. Review of Literature and clinicopathological analysis of 18 patients. *Oral Oncology* 43, 130-136, 2007.
- Myers LL, Nussenbaum B, Bradford CR et al: paranasal sinus malignancies: An 18 year single Institution experience. *Laryngoscope* 112: 1964, 2002.
- Adenoid Cystic Carcinoma and Mucoepidermoid Carcinoma of the maxillary sinus: Report of a 44-year experience of 25 cases from a Single Institution.
- Dulguerov P, Jacobsen MS, Allal AS, et al: Nasal and paranasal carcinoma: Are we making a Progress? A series of 220 patients and a systematic review. *Cancer* 92: 3012, 2001.
- Norlander T, Fordin JE, Selfverward.C et al: Decreasing incidence of malignant tumours of the Paranasal sinuses in Sweden. Analyses of 141 consecutive cases at Karolinska Hospital from 1960-1980. *Ann Otol Rhinol Laryngol* 112; 236 2003.
- Nishino H, Miyata M, Morita M, et al: Combined therapy with conservative surgery, Radiotherapy and regional chemotherapy for maxillary sinus carcinoma. *Cancer* 89: 1925, 2000
- Bhattacharya N: Factors affecting survival in maxillary sinus Cancer. *J Oral Maxillofac Surg* 61: 1016, 2003.
- Rajendran R, Shivapathasundharam B. Tumours of the Salivary gland. 6<sup>th</sup> Ed . New Delhi: Elsevier India; 2000. Shafers Textbook of oral pathology; pp. 219-53.
- Seifert G, Sobin LH. In International classification of tumours. New York: Springer-Verlag; 1991. Histological typing of salivary gland tumours.
- Bhattacharya N. Survival and Staging characteristics of non squamous cell malignancies of the Maxillary Sinus. *Arch Otolaryngol Head Neck Surg.* 2003; 129: 334-7.

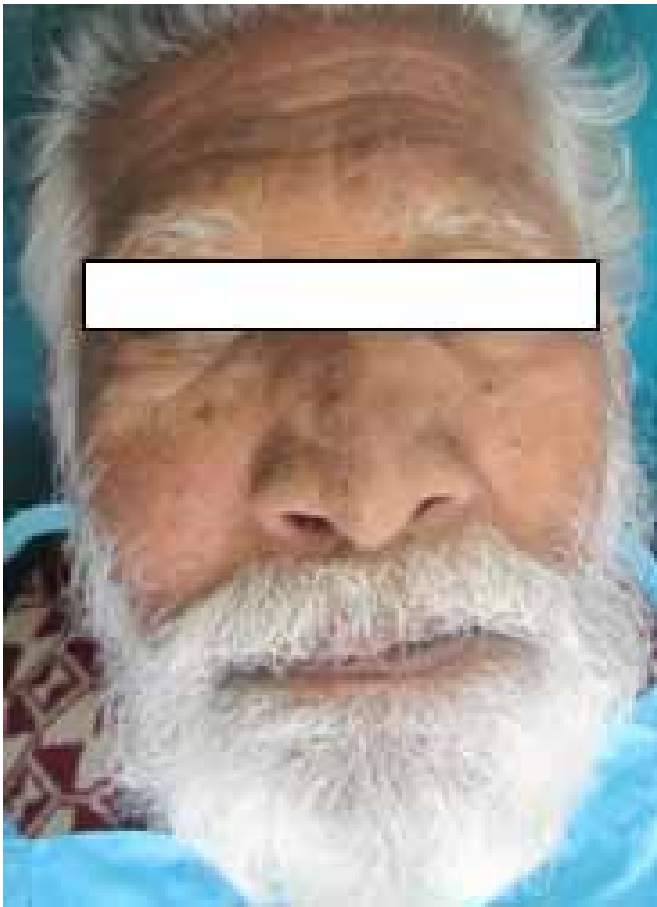

Figure 1

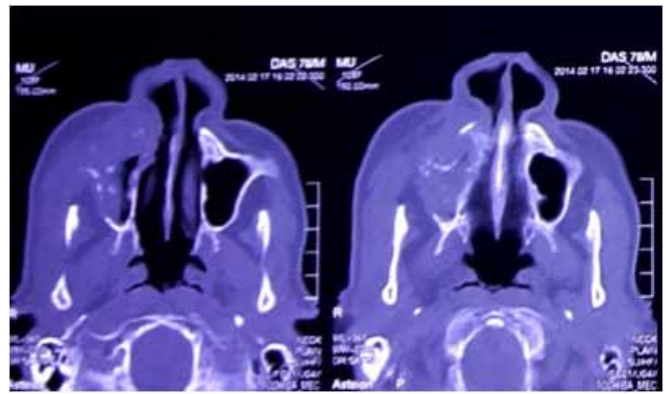


Figure 3

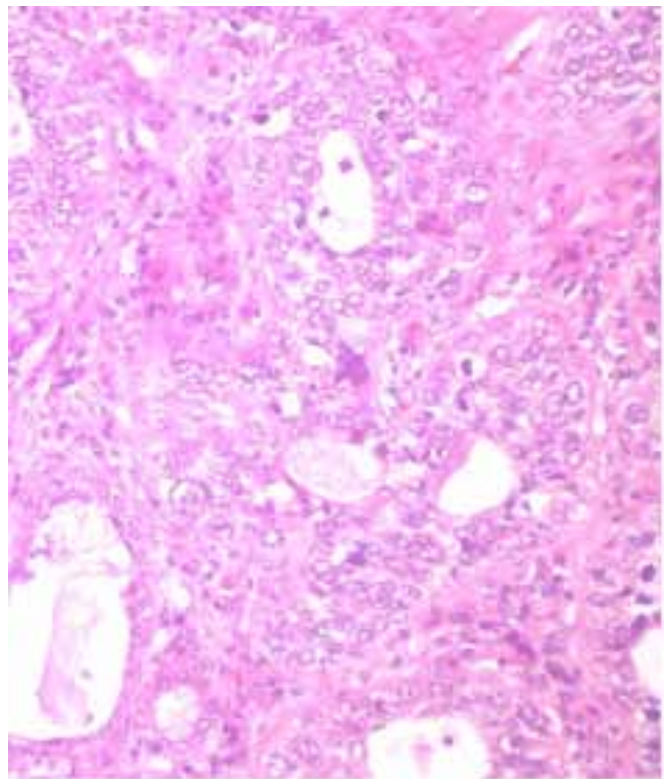


Figure 4

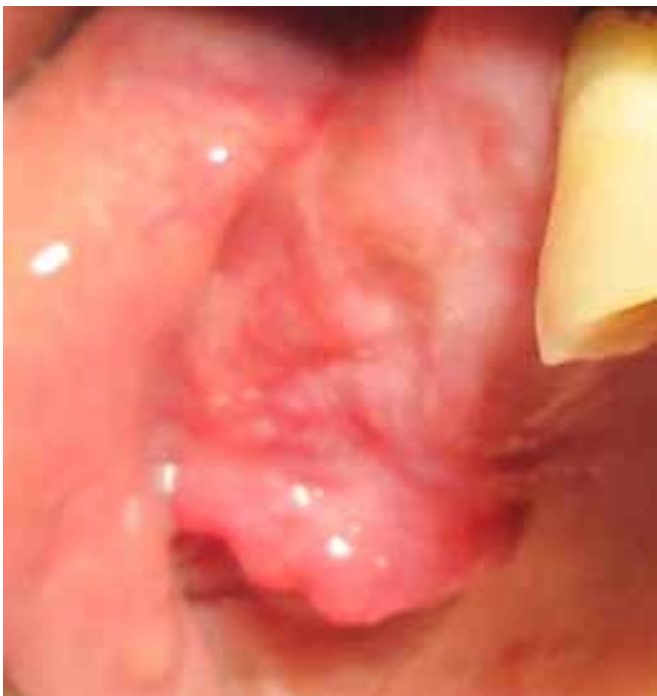

Figure 2