



SWEYER JAMES SYNDROME- A CASE REPORT

**Vishnukanth Govindaraj¹, Hariprasad Kalpakkam²,
Balla Nagamalli Kumar³, Suryakala Narayanaswamy²,
Manju R.¹, Dharm Prakash Dwivedi¹**

¹Assistant Professor, Department of Pulmonary Medicine, Jawaharlal Institute of Post graduate Medical Education and Research(JIPMER), Puducherry- 605006, India; ²Senior Resident, Department of Pulmonary Medicine, Jawaharlal Institute of Post graduate Medical Education and Research(JIPMER), Puducherry- 605006, India; ³Junior Resident, Department of Pulmonary Medicine, Jawaharlal Institute of Post graduate Medical Education and Research(JIPMER), Puducherry- 605006, India.

ABSTRACT

Unilateral hyperlucency on a chest x ray is not a uncommon occurrence. The causes vary from a simple rotation to a potentially life threatening pulmonary embolism. Sweyer James syndrome is one of the less known causes for unilateral hyperlucent lung which results as a sequelae to recurrent respiratory tract infections in childhood. We describe a patient with sweyer James syndrome who had no significant respiratory infections since childhood.

Key Words: Swyer james syndrome, Unilateral hyperlucency, CT chest

INTRODUCTION

Sweyer James syndrome was first described by Paul Robert Swyer and George C W James in the 1950s. Simultaneously the condition was also described by English physician William Mathieson Macleod, and by J Brett in France. Hence this syndrome is also referred to as Macleod syndrome, Brett syndrome and Janus syndrome.^{1,2} The syndrome is characterized by hyperlucency of one lung, lobe or part of a lobe due to pulmonary vascular abnormalities and alveolar over distension. The important pathological features of this syndrome include emphysema, bronchiectasis or bronchiolitis obliterans.³ The exact etiology of this syndrome is unknown but repeated episodes of respiratory tract infections particularly in the childhood is an important cause.⁴ Patients usually present in adult age and in many, a history of childhood respiratory infections is not obtained.

CASE DETAILS

A forty five year old agricultural labourer presented with symptoms of cough with minimal expectoration of ten days duration. He had similar symptoms atleast once a year for the last ten years. These symptoms subside with treatment. There was no seasonal aggravation of symptoms. He was not

a smoker and had no past history of tuberculosis. Upon examination he had no clubbing or cyanosis. He maintained saturation at room air. His heart rate, pulse rate and blood pressure were within normal limits. His respiratory system examination was normal. He was treated as upper respiratory tract infection and advised symptomatic management. Patient returned a week later with persistence symptoms. He was subjected for chest x ray which showed hyperlucency of the left hemithorax. (fig 1)Differential diagnosis of left sided pneumothorax, polands syndrome, sweyer James syndrome, pulmonary embolism, congenital lobar emphysema were considered. There was no rotation on the chest x ray. Patient was examined thoroughly and polands syndrome and pneumothorax were ruled out. A possibility of pulmonary embolism (?Westermark sign) and Sweyer James Syndrome were considered. Patient was subjected to high resolution computed tomography and pulmonary angiography scan. High resolution computed tomography(HRCT) scan of the chest showed decreased attenuation and decreased vascularity of the left lung with hyperlucency and bronchiectatic changes(fig 2). The right lung had normal vascularity. Pulmonary angiography was done which revealed a hypoplastic left pulmonary artery with reduced bronchovascular markings in left lung which confirmed the diagnosis.(fig 3) The patient had no echocardiographic evidence of pulmonary hypertension and arterial blood gas estimation was normal.

Corresponding Author:

Vishnukanth Govindaraj, Assistant Professor, Department of Pulmonary Medicine, Jawaharlal Institute of Post graduate Medical Education and Research (JIPMER), Puducherry- 605006

Received: 09.06.2015

Revised: 04.07.2015

Accepted: 29.07.2015

He is currently managed symptomatically and is on regular follow up.

DISCUSSION

Swyer-James syndrome(SJS) is usually suspected radiologically. On chest x ray there is hyperlucency of one lung field. Usually the left side is commonly affected⁵. Childhood viral respiratory infections particularly with measles, bordetella pertussis, tuberculosis, Mycoplasma pneumonia, influenza A, adenovirus types 3, 7, and 21 most commonly lead to development of SJS later⁴.

The pathological process in SJS is obliterative bronchitis with concomitant vasculitis. Following repeated viral infections the small bronchi and bronchioles are affected. A form of bronchiolitis obliterans develop which results in inflammation and fibrosis of the bronchiolar walls. As a result the lumen of the respiratory bronchioles are narrowed. The interalveolar septae undergo fibrotic changes with obliteration of pulmonary capillary bed⁶. This causes diminished blood flow to the major pulmonary artery segments, resulting in hypoplastic arterial development.

In addition, the reduction in ventilation causes a compensatory decrease in perfusion. Also consequent to bronchiolar obstruction the terminal air sacs expand which offers additional mechanical resistance to blood flow in the capillaries resulting in atrophy of vascular bed and hypoplasia of pulmonary artery⁷.

The disease symptom can manifest in the early infancy and childhood. Children present with recurrent history of respiratory tract infections. Cough can be productive or non productive. Shortness of breath and chest pain may be associated. Haemoptysis can occur. The symptoms depend on associated bronchiectasis⁸. Patients with no or minimal bronchiectasis are usually diagnosed in adult age by incidental chest radiography.

The classical chest x ray finding is unilateral hyperlucency. There can be mediastinal shift during inspiration and expiration. A mediastinal shift toward the affected side may occur on inspiration. Expiratory radiograph may demonstrate air trapping or a shift of the mediastinum towards the normal side. Associated Bronchiectatic changes may be seen.

Computed tomography(CT) is the investigation of choice in the diagnosis of this syndrome. On CT, Sweyer James syndrome appears as low attenuation hyperlucent areas due to decreased pulmonary perfusion of the lung with intervening areas of normal attenuation. Other findings include bronchiectasis, bronchiolectasis, atelectasis and scarring⁹. Ventilation – perfusion scans can help in confirmation of the ventilation perfusion defect. Matched ventilation and perfusion

defect can be seen¹⁰. Pulmonary angiography may reveal diminished size of the affected pulmonary artery. A number of other conditions can cause unilateral hyperlucency on chest x ray and they should be considered in the differential diagnosis of SJS. These include pneumothorax, pulmonary embolism, congenital lobar emphysema, polands syndrome, foreign body aspiration, post pneumonectomy, pulmonary agenesis. A few instances of misdiagnosis as pneumothorax with inadvertent intercostal tube placement are reported.⁸

There is no specific treatment for SJS. Treatment is usually supportive and is aimed at treating super added infections. Vaccination for influenza and pneumococci can be advised. Bronchodilators may be helpful in some patients. Prognosis depend on the underlying bronchiectasis¹¹. Long term oxygen may be needed in patients presenting with respiratory failure. Surgical treatment like lobectomy or pneumonectomy may be required in a few patients.

CONCLUSION

Sweyer James Syndrome is not an uncommon syndrome and has to be considered in the differential diagnosis of unilateral hyperlucency and when suspected a CT scan can help in establishing the diagnosis.

ACKNOWLEDGEMENT

The authors would like to thank Dr. Ravindra Chary, Junior resident in the department of Pulmonary medicine for his help in the preparation of this manuscript. Authors also acknowledge the immense help received from the scholars whose articles are cited and included in references of this manuscript. The authors are also grateful to authors / editors / publishers of all those articles, journals and books from where the literature for this article has been reviewed and discussed.

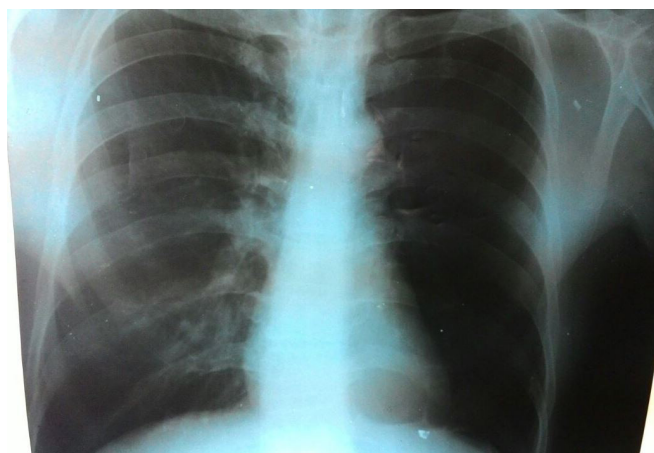


Figure 1: Chest x ray showing hyperlucency of the left hemithorax

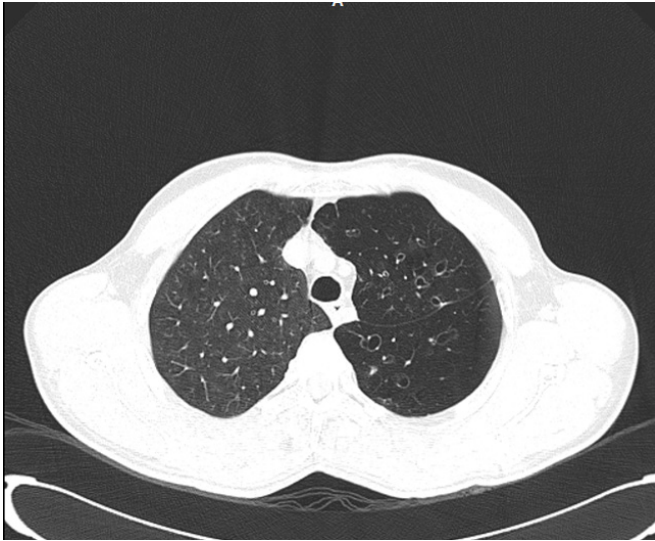


Figure 2: High resolution chest CT showing decreased attenuation, avascularity and bronchiectatic changes of the left lung

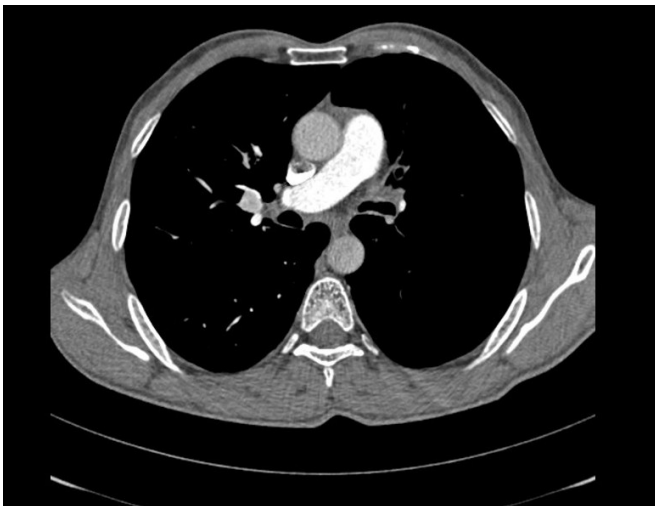

Figure 3: Pulmonary angiogram showing no contrast in the left pulmonary artery.

REFERENCES

1. www.radiopedia.org/articles/sweyer_james_syndrome. ACCESSED ON 1.5.2015.
2. Swyer PR, James GC. A case of unilateral pulmonary emphysema. *Thorax* 1953;8:133–136.
3. Kanwal Fatima Khalil and Waseem Saeed. Swyer-James-MacLeod Syndrome. *Journal of the College of Physicians and Surgeons Pakistan* 2008, Vol. 18 (3): 190-192.
4. Schlesinger C, Veeraraghavan S, Koss MN. Constrictive (obliterative) bronchiolitis. *Curr Opin Pulm Med* 1998;4:288–293.
5. Abba AA, Al-Mobeireek AF. Clinical spectrum of Swyer-James-MacLeod syndrome in adults. *Saudi Med J* 2003; 24:195-8.
6. Schlesinger C, Meyer CA, Veeraraghavan S, Koss MN. Constrictive (obliterative) bronchiolitis: diagnosis, etiology, and a critical review of the literature. *Ann Diagn Pathol* 1998;2:321–334.
7. Mathur S, Gupta SK, Sarda M, Jaipal U. Swyer-James-MacLeod syndrome with emphysematous bulla. *J Indian Med Assoc* 1995;93:150–154.
8. Sulaiman A, Cavaille A, Vaunois B, Tiffet O. Swyer-James-MacLeod syndrome; repeated chest drainages in a patient misdiagnosed with pneumothorax. *Interact Cardio Vasc Thorac Surg* 2009;8:482–484.
9. Umesh C. Parashari, Ragini Singh, Anit Parihar, Pallavi Aga, Rajesh Yadav. Diagnostic role of magnetic resonance angiography in Swyer James syndrome: Case series of two cases. *Lung India*. 2010 Jul-Sep; 27(3): 161–163.
10. Arslan N, Ilgan S, Ozkan M, Yuksekol I, Bulakbasi N, Pabuscuy, et al. Utility of ventilation and perfusion scan in the diagnosis of young military recruits with an incidental finding of hyperlucent lung. *Nucl Med Commun*. 2001;22:525–30.
11. Gopinath A, Strigun D, Banyopadhyay T. Swyer-James syndrome. *Conn Med* 2005; 69:325-7.