



# A DETAILED STUDY OF ABSENCE OF EOSINOPHILIA IN PATIENTS WITH HOOKWORM INFECTION DIAGNOSED BY DOING UPPER GASTRO-INTESTINAL ENDOSCOPY

**Govindarajalu Ganesan**

Associate Professor, Department of General Surgery, Aarupadai Veedu Medical College and Hospital, Puducherry - 607402, India.

## ABSTRACT

**Objective:** Many studies have shown the presence of eosinophilia in hookworm infection. But so far detailed study was not done to know about the absence of eosinophilia in hookworm infection. Hence a detailed study was done to know about the absence of eosinophilia in hookworm infection diagnosed by doing upper gastro-intestinal endoscopy in our institute.

**Methods:** A study of 1137 patients who had undergone upper gastro-intestinal endoscopy for a period of four years and eight months from May 2009 to December 2013 was carried out in our institute to know about the absence of eosinophilia in hookworm infection diagnosed by doing upper gastro-intestinal endoscopy in our institute.

**Results:** Out of these 1137 patients, 14 patients found to have hookworms in duodenum while doing upper gastro-intestinal endoscopy were taken into consideration for our study. Out of these 14 patients with hookworms in duodenum, as many as 10 patients with hookworms in duodenum were found to have eosinophilia [71%]. But 4 patients with hookworms in duodenum did not have any eosinophilia [29%]. Out of these 4 patients without eosinophilia with hookworm infection, 3 patients without eosinophilia with hookworm infection had anaemia [75%].

**Conclusion:** Hence, eosinophilia can sometimes be absent in hookworm infection. But 3 out of 4 patients without eosinophilia with hookworm infection had anaemia in our study. Hence anaemia is an important indicator of hookworm infection which is not associated with eosinophilia.

**Key Words:** Absence of eosinophilia, Presence of anaemia, Hookworm infection, Upper gastro-intestinal endoscopy

## INTRODUCTION

Many studies have also shown the presence of eosinophilia in hookworm infection (1 to 14) . But so far detailed study was not done to know about the absence of eosinophilia in hookworm infection. Hence a detailed study was done to know about the absence of eosinophilia in hookworm infection diagnosed by doing upper gastro-intestinal endoscopy in our institute.

## MATERIALS AND METHODS

This study was conducted in the department of general surgery, Aarupadai Veedu Medical College and Hospital,

Puducherry. A study of 1137 patients who had undergone upper gastro-intestinal endoscopy for a period of four years and eight months from May 2009 to December 2013 was carried out in our institute. In each of these 1137 patients, the first and second part of duodenum were carefully examined to find out the presence of hookworms. In all the patients found to have hookworms in duodenum, investigations were done to know about the presence or absence of eosinophilia and anaemia. Anaemia is defined as haemoglobin < 12g/dl or 12g% in women (15 to 22) and haemoglobin < 13g/dl or 13g% in men (21, 22). Mild anaemia is taken as haemoglobin 10to12g/dl or 10to12 g%, moderate anaemia is taken as haemoglobin 7to10g/dl or 7to10 g% and severe anaemia is taken as haemoglobin <7g/dl or 7g% (23). Eosinophilia is defined as eosinophils > = 500 cells/cu.mm (24). Se-

### Corresponding Author:

Govindarajalu Ganesan, Associate Professor, Department of General Surgery, Aarupadai Veedu Medical College and Hospital, Puducherry - 607402; Email: drganesan@gmail.com

Received: 03.07.2015

Revised: 01.08.2015

Accepted: 01.10.2015

vere eosinophilia or hypereosinophilia is defined as eosinophils > 1000 cells/cu.mm (4). The results were found as given below.

## RESULTS

1. Out of these 1137 patients, 14 patients found to have hookworms in duodenum while doing upper gastro-intestinal endoscopy were taken into consideration for our study.
2. Out of these 14 patients with hookworms in duodenum, as many as 10 patients with hookworms in duodenum were found to have eosinophilia [71%].
3. But 4 patients with hookworms in duodenum did not have any eosinophilia [29%].
4. Out of these 4 patients without eosinophilia with hookworm infection, 3 patients without eosinophilia with hookworm infection had anaemia [2 patients had mild anaemia and 1 patient had severe anaemia].
5. One patient without eosinophilia with hookworm infection also had absence of anaemia.

**Hence the 4 patients without eosinophilia with hookworm infection can be divided into 3 groups as follows**

- a. Absence of both eosinophilia and anaemia in hookworm infection [1 patient].
- b. Mild anaemia without eosinophilia with hookworm infection [2 patients]
- c. Severe anaemia without eosinophilia with hookworm infection [1 patient]

## DISCUSSION

**a. Absence of both eosinophilia and anaemia in hookworm infection [1 patient].**

1. One patient with hookworm infection neither had eosinophilia [absolute eosinophil count - 160 cells/cu.mm] nor had anaemia [haemoglobin - 14g%] which is of extremely great significance.
2. This patient had adequate amount of haemoglobin indicating clearly that the patient was in the extremely early stage of hookworm infection.
3. Eosinophilia was probably not present since the patient was in such extremely early stage of hookworm infection.
4. Eosinophilia only peaks at 5 to 9 weeks after the onset of infection, a period that coincides with the appearance of adult hookworms in the intestine (10).

**b. Mild anaemia without eosinophilia with hookworm infection [2 patients]**

1. 2 patients without eosinophilia with hookworm infection had mild anaemia [1. haemoglobin 11.2g% ,

absolute eosinophil count - 396 cells/cu.mm 2. haemoglobin 10g% , absolute eosinophil count - 364 cells/cu.mm].

2. The single hookworm in duodenum found in the patient with mild anaemia [haemoglobin 10 g%] without eosinophilia [absolute eosinophil count - 364 cells/cu.mm] is shown in Fig 1, 2.
3. The hookworm in duodenum is identified by its bent head which looks like a hook (Fig1) and by its S-shaped appearance (25) (Fig1) .

**c. Severe anaemia without eosinophilia with hookworm infection [1 patient]**

1. Severe anaemia is due to significant loss of blood due to large number of hookworms and very heavy burden of hookworm infection and indicates severe hookworm infection.
2. Severe anaemia without eosinophilia with hookworm infection was present in one patient in our study [haemoglobin 2.1g%, absolute eosinophil count - 366 cells/cu.mm].
3. Hence even in patients with severe anaemia due to severe hookworm infection, eosinophilia need not be present.
4. Hence significant anaemia always occurs in severe hookworm infection, but eosinophilia can sometimes be absent even in severe hookworm infection.
5. Various other studies have also shown the presence of severe anaemia without eosinophilia in hookworm infection (25 to 29).
6. Multiple hookworms in duodenum without eosinophilia [absolute eosinophil count - 366 cells/cu.mm] and with severe anaemia [haemoglobin 2.1 g%] indicating severe hookworm infection is shown in Fig 3.

## CONCLUSION

1. 3 out of 4 patients without eosinophilia with hookworm infection in our study had anaemia. Of these 3 patients, 1 patient without eosinophilia had severe anaemia due to severe hookworm infection.
2. Hence significant anaemia always occurs in severe hookworm infection, but eosinophilia can sometimes be absent even in severe hookworm infection.
3. Hence upper gastro intestinal endoscopy should be done to confirm the presence of hookworms in all patients with anaemia even when there is no eosinophilia.

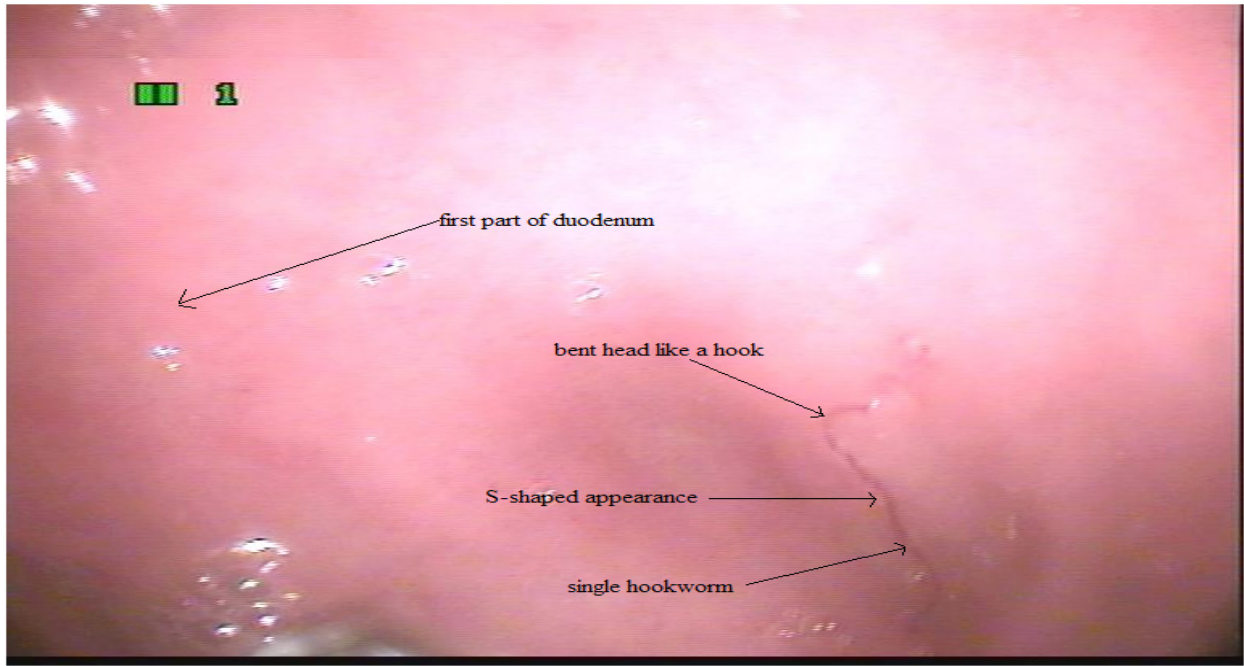
## ACKNOWLEDGEMENT

The author sincerely thanks the staff nurse Nithya who was assisting the author while doing endoscopy and the staff nurses A.K. Selvi and Nithya for their immense help rendered to the author while conducting this work. The author

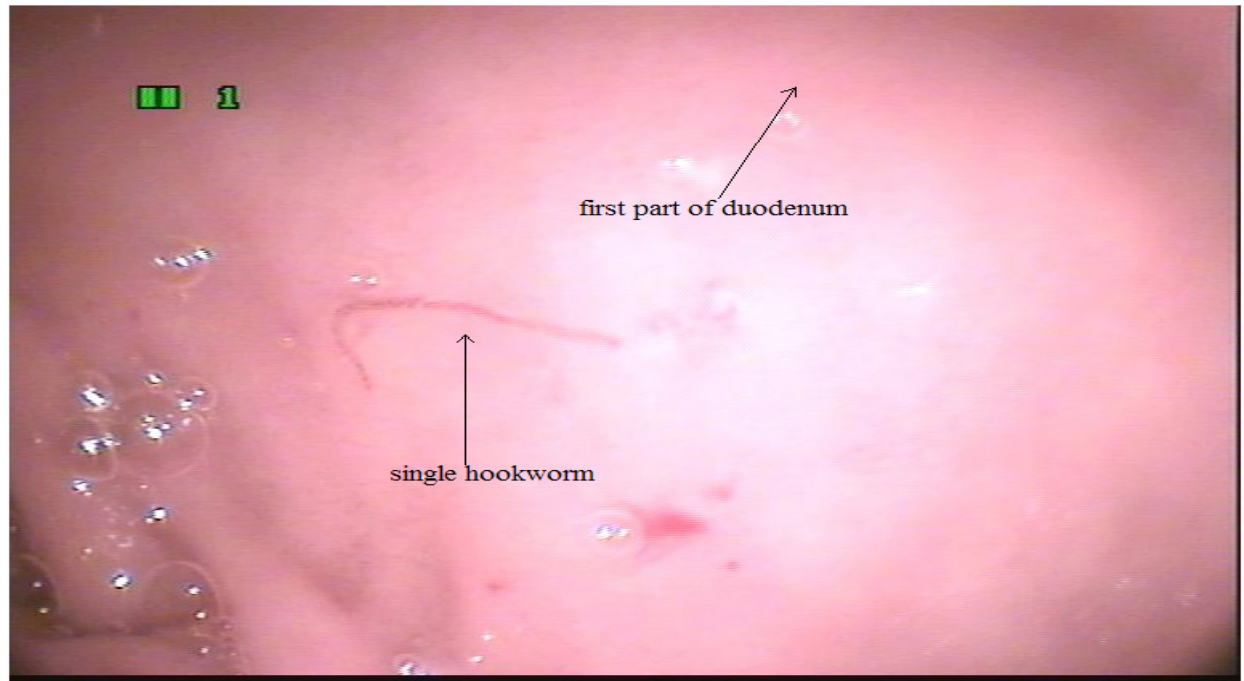
acknowledges the immense help received from the scholars whose articles are cited and included in references of this manuscript. The author is also grateful to authors / editors / publishers of all those articles, journals and books from where the literature for this article has been reviewed and discussed. The author is extremely grateful to IJCRR editorial board members and IJCRR team of reviewers who have helped to bring quality to this manuscript.

## REFERENCES

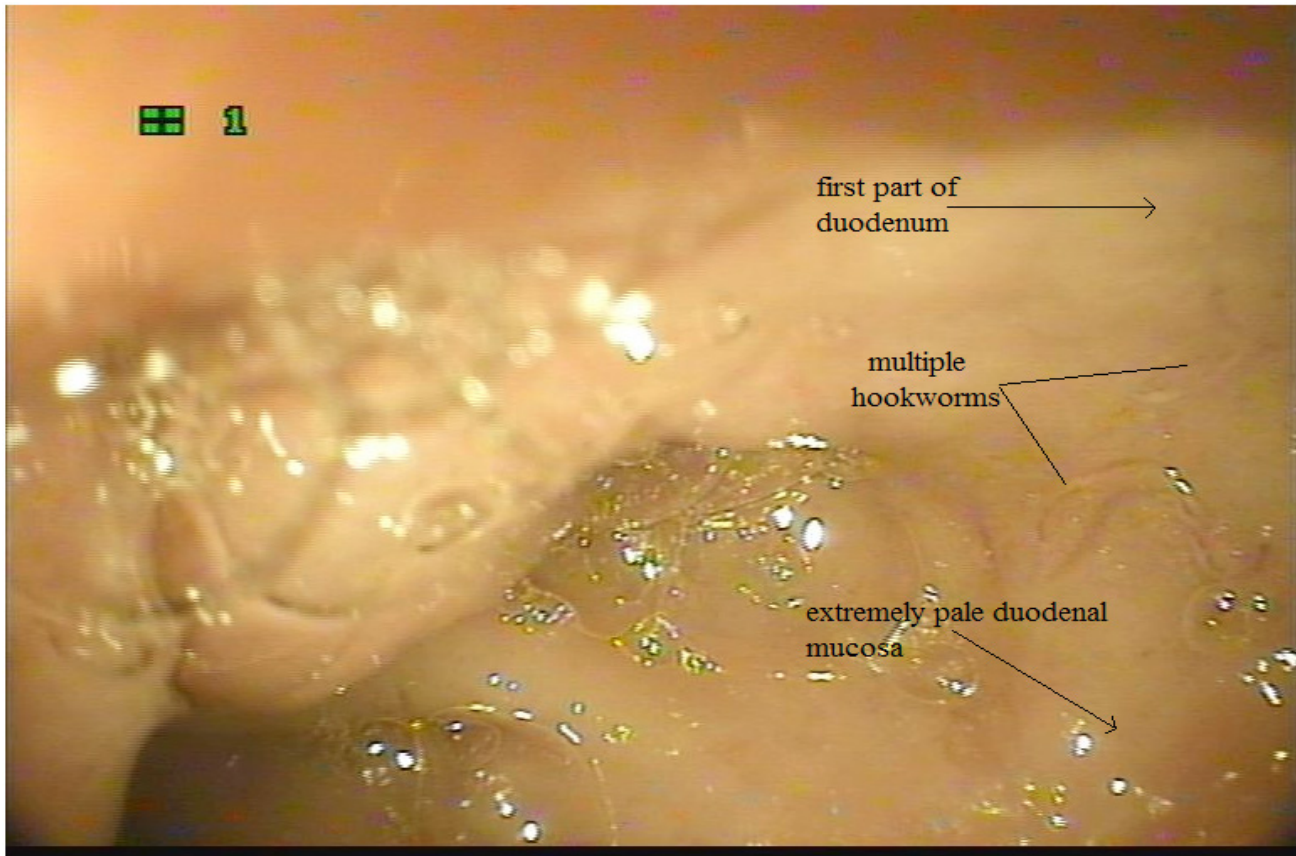
- Nutman TB, Ottesen EA, Ieng S, Samuels J, Kimball E, Lutkowski M, Zierdt WS, Gam A, Neva FA. Eosinophilia in Southeast Asian refugees: evaluation at a referral center. *J Infect Dis.* 1987 Feb;155(2):309-
- Triteerapapab S, Nuchprayoon I. Eosinophilia, anemia and parasitism in a rural region of north-west Thailand. *Southeast Asian J Trop Med Public Health.* 1998 Sep;29(3):584-90.
- Lawn SD1, Grant AD, Wright SG Case reports: acute hookworm infection: an unusual cause of profuse watery diarrhoea in returned travellers *Trans R Soc Trop Med Hyg.* 2003 Jul-Aug;97(4):414-5.
- Heukelbach J, Poggensee G, Winter B, Wilcke T, Kerr-Pontes LR, Feldmeier H Leukocytosis and blood eosinophilia in a polyparasitised population in north-eastern Brazil. *Trans R Soc Trop Med Hyg.* 2006 Jan;100(1):32-40. Epub 2005 Sep 23.
- Verboeket SO1, Van den Berk GE., Arends JE, van Dam AP, Peringa J, Jansen RR. Hookworm with hypereosinophilia: atypical presentation of a typical disease. *J Travel Med.* 2013 Jul-Aug;20(4):265-7.
- Kato T, Kamoi R, Iida M, Kihara T. Endoscopic diagnosis of hookworm disease of the duodenum *J Clin Gastroenterol.* 1997 Mar;24(2):100-102.
- Anjum Saeed, Huma Arshad Cheema, Arshad Alvi, Hassan Suleman. Hookworm infestation in children presenting with malena -case series *Pak J Med Res Oct - Dec 2008;47(4) :98-100.*
- Wang CH, Lee SC, Huang SS, Chang LC. Hookworm infection in a healthy adult that manifested as severe eosinophilia and diarrhea. *J Microbiol Immunol Infect.* 2011 Dec;44(6):484-7. Epub 2011 May 23.
- Yan SL, Chu YC. Hookworm infestation of the small intestine *Endoscopy* 2007; 39: E162±163.
- Maxwell C, Hussain R, Nutman TB, Poindexter RW, Little MD, Schad GA, Ottesen EA. The clinical and immunologic responses of normal human volunteers to low dose hookworm (*Necator americanus*) infection. *Am J Trop Med Hyg.* 1987 Jul;37(1):126-34.
- Kucik CJ, Martin GL, Sortor BV. Common intestinal parasites. *Am Fam Physician.* 2004 Mar 1;69(5) :1161-8.
- A Rodríguez, E Pozo, R Fernández, J Amo, T Nozal. Hookworm disease as a cause of iron deficiency anemia in the prison population *Rev Esp Sanid Penit* 2013; 15: 63-65.
- Li ZS1, Liao Z, Ye P, Wu RP Dancing hookworm in the small bowel detected by capsule endoscopy: a synthesized video. *Endoscopy.* 2007 Feb;39 Suppl 1:E97. Epub 2007 Apr 18.
- McSorley, H. J., and Loukas, A. The immunology of human hookworm infections. *Parasite immunology,* 2010;32(8), 549-559.
- Kabir, Y., Shahjalal, H. M., Saleh, F., and Obaid, W. Dietary pattern, nutritional status, anaemia and anaemia-related knowledge in urban adolescent college girls of Bangladesh. *J PMA. The Journal of the Pakistan Medical Association,* 2010; 60(8), 633.
- Ahmed, F., Khan, M. R., Islam, M., Kabir, I., and Fuchs, G. J.. Anaemia and iron deficiency among adolescent schoolgirls in peri-urban Bangladesh. *European journal of clinical nutrition,* 2000 ;54(9), 678-683.
- Ahmed F1, Khan MR, Karim R, Taj S, Hyderi T, Faruque MO, Margetts BM, Jackson AA. Serum retinol and biochemical measures of iron status in adolescent schoolgirls in urban Bangladesh. *Eur J Clin Nutr.* 1996 Jun;50(6):346-51.
- Foo, L. H., Khor, G. L., Tee, E. S., and Prabakaran, D.. Iron status and dietary iron intake of adolescents from a rural community in Sabah, Malaysia. *Asia Pacific journal of clinical nutrition,* 2004 ;13(1), 48-55.
- Chandyo, R. K., Strand, T. A., Ulvik, R. J., Adhikari, R. K., Ulak, M., Dixit, H., and Sommerfelt, H. Prevalence of iron deficiency and anemia among healthy women of reproductive age in Bhaktapur, Nepal. *European journal of clinical nutrition,* 2007;61(2), 262-269.
- Sarita Modi, Bose Sukhwant, Study of iron status in female medical students, *Indian Journal of Basic and Applied Medical Research;* March 2013: Issue-6, Vol.-2, P. 518-526.
- Sikosana, P. L., Bhebhe, S., and Katuli, S.. A prevalence survey of iron deficiency and iron deficiency anaemia in pregnant and lactating women, adult males and pre-school children in Zimbabwe. *Central African Journal of Medicine,* 1998;44(12), 297-304.
- WHO. Iron deficiency anaemia: assessment, prevention, and control. a guide for programme managers. Geneva, Switzerland: World Health Organization, 2001. (WHO/NHD/01.3.)
- Hyder, S. M. Z., Persson, L. Å., Chowdhury, M., Lönnerdal, B. O., and Ekström, E. C.. Anaemia and iron deficiency during pregnancy in rural Bangladesh. *Public health nutrition,* 2004 ; 7(8), 1065-1070.
- Meltzer E, Percik R, Shatzkes J, Sidi Y, Schwartz E. Eosinophilia among returning travelers: a practical approach *Am J Trop Med Hyg.* 2008 May;78(5):702-9.
- Cedrón-Cheng H, Ortiz C .Hookworm Infestation Diagnosed by Capsule Endoscopy. *J Gastroint Dig Syst* 2011 S1:003. doi: 10.4172/2161-069X.S1-003.
- Kuo YC, Chang CW, Chen CJ, Wang TE, Chang WH, Shih SC . Endoscopic Diagnosis of Hookworm Infection That Caused Anemia in an Elderly Person. *International Journal of Gerontology.* 2010 ; 4(4) : 199-201.
- Kalli T1, Karamanolis G, Triantafyllou K Hookworm infection detected by capsule endoscopy in a young man with iron deficiency. *Clin Gastroenterol Hepatol.* 2011 Apr;9(4):e33
- Chen JM1, Zhang XM, Wang LJ, Chen Y, Du Q, Cai JT. Overt gastrointestinal bleeding because of hookworm infection. *Asian Pac J Trop Med.* 2012 Apr;5(4):331-2.
- Wu KL, Chuah SK, Hsu CC, Chiu KW, Chiu YC, Changchien CS. Endoscopic Diagnosis of Hookworm Disease of the Duodenum: A Case Report. *J Intern Med Taiwan* 2002;13:27-30.



**Figure 1:** Single hookworm in duodenum with its bent head like a hook and S-shaped appearance in the patient with mild anaemia[haemoglobin 10 g%] without eosinophilia[absolute eosinophil count - 364cells/cu.mm]



**Figure 2:** Single hookworm in duodenum in the same patient with mild anaemia without eosinophilia[different view] .



**Figure 3:** Multiple hookworms in duodenum without eosinophilia [absolute eosinophil count - 366cells/cu.mm] and with severe anaemia [haemoglobin 2.1 g%] showing extremely pale duodenal mucosa due to severe anaemia.