



IJCRR

Section: Healthcare

ISI Impact Factor  
(2019-20): 1.628

IC Value (2019): 90.81

SJIF (2020) = 7.893



Copyright@IJCRR

# A Case of Cryptococcal Osteomyelitis in a Solid Organ Transplant Patient

Sushanth K<sup>1</sup>, Goyal S<sup>2</sup>, Jeganathan JK<sup>3</sup>, Pavan MR<sup>3</sup>

<sup>1</sup>Consultant Nephrologist, Kasturba Medical College, Mangalore, Manipal Academy of Higher Education, Manipal, Karnataka, India;

<sup>2</sup>Registrar in Nephrology Department, Kasturba Medical College, Mangalore, Manipal Academy of Higher Education, Manipal, Karnataka, India;

<sup>3</sup>Associate Professor, Kasturba Medical College, Mangalore, Manipal Academy of Higher Education, Manipal, Karnataka, India.

## ABSTRACT

**Introduction:** Infections in transplant patients may be missed as they do not present with the usual clinical features. This leads to a delay in the diagnosis and thereby resulting in delayed treatment. Atypical organisms are also responsible for a variety of infections in these immunosuppressed individuals. The following case illustrates these points.

**Aim:** To report an unusual manifestation of *cryptococcal* infection.

**Case Report:** This is a case of a 63-year post-renal transplant lady. Three years after the transplant, she presented with a headache. CNS examination did not reveal any abnormality. Non-contrast CT showed well-defined hypodense collection measuring 2.8x 4.1x 3.5 in the right suboccipital region deep to the muscular plane with erosion and defect in the subjacent right occipital bone. Pus culture showed *cryptococcus*. She underwent drainage of abscess and surgery for osteomyelitis. She received 3 weeks of treatment with liposomal amphotericin B, followed by oral fluconazole.

**Discussion:** Bone involvement occurs in only 5% of cases of *cryptococcus*. It most often affects the lumbar spine or lower extremities and rarely at other sites.

**Conclusion:** It is important to be aware of this entity especially when managing immune-compromised individuals.

**Key Words:** Amphotericin, Cryptococcus, Fungus, Osteomyelitis, Renal transplant, Occipital bone

## INTRODUCTION

Transplant patients are susceptible to a variety of organisms. Due to this reason, atypical organisms like viruses and fungi form an important aetiology in these individuals. These patients may not develop overt symptoms and signs as exhibited by immune-competent individuals. Hence the diagnosis of infection is more challenging in these cases. In addition to this, graft rejection is also an important problem in these individuals which presents with a variety of clinical pictures and further complicates the clinical presentation. These two issues need a different set of approaches in their evaluation and treatment. Diagnosing these entities early and treating them early will have a significant impact on the morbidity and mortality of these individuals.

## CASE REPORT

A 63-year-old female, known case of focal segmental glomerulosclerosis (biopsy-proven), Hypertension, end-stage

renal disease underwent the deceased renal transplant in 2016 with no history of acute or chronic rejection. She was on dialysis for a year before the renal transplant. Post-transplant she was initiated on triple-drug immunosuppressants with tacrolimus, azathioprine, prednisolone along antihypertensive tablets. After 3 years post-transplant, she developed new-onset diabetes mellitus. This time patient presented with complaints of headache. On examination, she did not have any positive findings. CT head done showed nothing significant. She was treated with broad-spectrum antibiotics but she continued to have the same complaints mainly confined to the occipital region even after 2 months so a repeat non-contrast CT head was done. It showed well-defined hypodense collection measuring 2.8x 4.1x 3.5 in the right suboccipital region deep to the muscular plane with erosion and defect in the subjacent right occipital bone as shown in Fig 1. The defect was 16mm suggestive of osteomyelitis. There was no intracranial extension of the abscess. Other routine investigations were done, renal function was normal with a creatinine of 1.02 mg/dl. She underwent drainage of abscess

### Corresponding Author:

**Jeganathan Jayakumar**, Associate Professor, Kasturba Medical College, Mangalore, Manipal Academy of Higher Education, Manipal, Karnataka, India; Ph: 9343351015; Email: [jayakumar.j@manipal.edu](mailto:jayakumar.j@manipal.edu)

ISSN: 2231-2196 (Print)

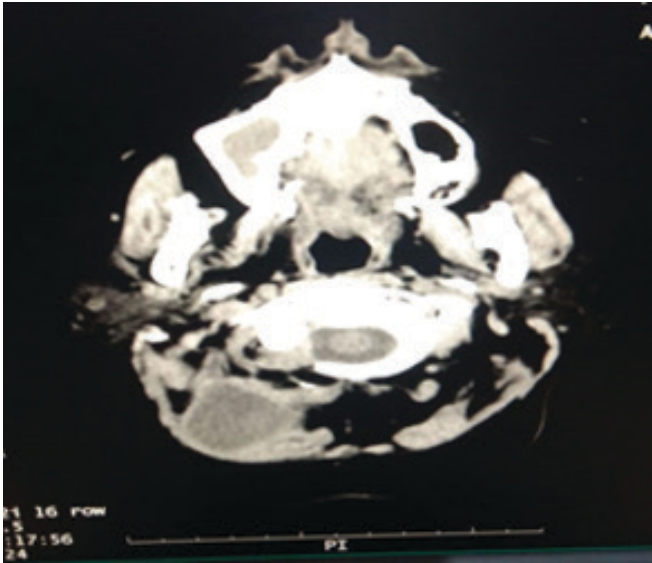
ISSN: 0975-5241 (Online)

Received: 17.01.2021

Revised: 02.02.2021

Accepted: 19.04.2021

Published: 26.09.2021



**Figure 1:** CT showing the suboccipital collection.

and surgery for osteomyelitis under general anaesthesia with broad-spectrum antibiotic coverage. Tacrolimus dose was reduced as per tacrolimus levels. Bony chips were sent for histopathological examination and cultures. After post-procedure, she was started on empirical antifungal treatment with liposomal amphotericin B with a dose of 100mg/day for 3 weeks under strict monitoring of renal function and serum potassium levels.

## RESULTS

During treatment histopathology was suggestive of suppurative granulomatous inflammation of fungal aetiology, morphology was similar to *cryptococcus*. She received 3 weeks of treatment with liposomal amphotericin B and was symptomatically better. On discharge her renal functions were normal and she was advised oral fluconazole for the next 3 months. She completed the 3 months course of fluconazole. Presently she is on triple-drug immunosuppressant along with anti-hypertensives and insulin. Her renal functions are normal. She is asymptomatic & the wound has healed completely.

## DISCUSSION

*Cryptococcus neoformans* is an encapsulated yeast organism that can cause severe illness or death.<sup>1</sup> It predominantly causes significant infections in immune-compromised individuals.<sup>2</sup> It is associated with high mortality and hence early diagnosis is necessary to improve the prognosis.<sup>3</sup> The incidence of *cryptococcal* infection in solid organ transplant patients is around 2.8%.<sup>4</sup> Osteomyelitis is a rare manifesta-

tion of *cryptococcal* infection for which there is often a significant delay in reaching a diagnosis and treatment. Predisposing factors for *cryptococcal* osteomyelitis include solid organ transplant, immunosuppressant medication use, diabetes mellitus and HIV. *Cryptococcal* infection in solid organ transplant patients most frequently occurs in the late post-transplant period, often between 16 and 21 months.<sup>5</sup> It can be due to reactivation of pre-existing host colonisation or can represent primary infection after new exposure. Infectious diseases society of America (IDSA) recommends a three-stage treatment regimen. This begins with an induction phase consisting of liposomal amphotericin (3–5 mg/kg/day) and flucytosine (100 mg/kg/day) for at least 2 weeks.<sup>6</sup> This can be extended if the infection is refractory to treatment. However, it is important to closely monitor the patient for nephrotoxicity during this treatment, as it is a common side effect of amphotericin. The induction phase is followed by a consolidation phase consisting of fluconazole 400–800 mg/day for 8 weeks.<sup>7</sup> Finally, it is recommended that the patient undergoes a period of prolonged maintenance using lower dose fluconazole at 200–400 mg/day for 6 to 12 months.<sup>8</sup> As *cryptococcus neoformans* is not a common organism responsible for bone lesions and with the clinical and radiological signs being non-specific, the diagnosis often gets delayed and hence results in significant morbidity and mortality.

## CONCLUSION

This case stresses the importance of considering underlying osteomyelitis even in an unusual location such as the occiput in post-transplant patients. Additionally, atypical organisms such as fungal infections can cause osteomyelitis or abscess in these patients. This case also shows the importance of following up with these patients carefully and repeating investigations if the initial evaluation does not pick up the abnormality so that the diagnosis is not missed.

## ACKNOWLEDGEMENT

Authors acknowledge the immense help received from the scholars whose articles are cited and included in references of this manuscript. The authors are also grateful to authors/editors/publishers of all those articles, journals and books from where the literature for this article has been reviewed and discussed.

## Authors' Contribution

1. Dr B Sushanth Kumar: Case report conception, supervision, revision
2. Dr GoyalShanki: Conception, background literature and discussion.
3. Dr JeganathanJayakumar: Conception, data collection, writing the manuscript, revision of the article.

4. Dr M R Pavan: Conception, preparation of the manuscript, revision of the article.

**Source of funding:** Self

**Conflict of interest:** Nil

## REFERENCES

1. Pappas PG, Perfect JR, Cloud GA, Larsen RA, Pankey GA, Lancaster DJ et al. *Cryptococcosis* in human immunodeficiency virus-negative patients in the era of effective azole therapy. *Clin Infect Dis*. 2001;33(5):690-9.
2. Charmi NS, Mannu RJ, Manish GP, Parul V. Isolation of *Cryptococcus neoformans* from abscess aspirate in a pulmonary tuberculosis patient. *Int J Cur Res Rev*. 2016;8(4):47-49.
3. Rajani S, Nandini D, Shalini M, Dinesh S, Charoo H. Prevalence of *cryptococcal* meningitis amongst HIV seropositive cases from a tertiary care hospital. *Int J Cur Res Rev*. 2014;6(14):32-37.
4. Henaó-Martínez AF, Beckham JD. *Cryptococcosis* in solid organ transplant recipients. *Curr Opin Infect Dis* 2015;28(4):300-7.
5. Wood L, Miedzinski L. Skeletal *cryptococcosis*: Case report and review of the literature. *Can J Infect Dis*. 1996;7(2):125-32.
6. Medaris LA, Ponce B, Hyde Z, Delgado D, Ennis D, Lapidus et al. *Cryptococcal* osteomyelitis: a report of 5 cases and a review of the recent literature. *Mycoses*. 2016;59(6):334-42.
7. Perfect JR, Dismukes WE, Dromer F, Goldman DL, Graybill JR, Hamill RJ et al. Clinical practice guidelines for the management of *cryptococcal* disease: 2010 update by the infectious diseases society of America *Clin Infect Dis*. 2010;50(3):291-322.
8. Singh N, Forrest G; AST Infectious Diseases Community of Practice. *Cryptococcosis* in solid organ transplant recipients. *Am J Transplant*. 2009;9(4):S192-8.