International Journal of Current Research and Review
DOI: http://dx.doi.org/10.31782/IJCRR.2021.SP269

Scopus

Original Research

IJCRR
Section: Healthcare
ISI Impact Factor (2019-20): 1.628
IC Value (2019): 90.81
SJIF (2020) = 7.893

Spectrum of Atypical HRCT Chest Imaging Features in Covid 19 Patients from Eastern India – A Revelation

Rohit Arora[1], Kamal K. Sen[2], Sangram Panda[3], Sudhansu Sekhar Mohanty[3], Mayank Goyal[1], Roopak Dubey[1]

[1]Junior Resident, Department of Radio-Diagnosis, Kalinga Institute of Medical Sciences, Bhubaneswar, Odisha, India; [2]Professor and Head, Department of Radio-Diagnosis, Kalinga Institute of Medical Sciences, Bhubaneswar, Odisha, India; [3]Assistant Professor, Department of Radio-Diagnosis, Kalinga Institute of Medical Sciences, Bhubaneswar, Odisha, India.

ABSTRACT

Background: Coronavirus Disease 2019 (COVID-19), a severe respiratory syndrome is a pandemic, known to affect patients of all age groups with varied imaging features.

Aim and Objective: To identify and categorize the additional *Atypical* imaging features detected in COVID 19 patients from eastern India.

Method: HRCT images of 1300 COVID-19 patients without any known co-morbid conditions and showing positive HRCT findings were analyzed and evaluated for prevalence of atypical imaging features. HRCT images were categorized into typical, atypical and indeterminate. Further the additional atypical features were evaluated.

Results: Out of 1300 patients, 320 (24.6%) patients showed atypical imaging features, 860 patients (64.6%) were in the Typical and 140 (10.7%) were in the indeterminate category. Amongst patients with atypical imaging features, we found that isolated lobar or segmental consolidation without associated GGO's prevalent in 5.6% of patients, discrete pulmonary nodules which include both centrilobular and tree-in-bud nodular patterns in 42%, mediastinal/hilar lymphadenopathy in 9.3%. About 11% of patients had pleural effusion and 1.2% demonstrated pneumothorax and pneumomediastinum. Linear or subsegmental atelectasis was noted in 66% of patients.

Conclusion: Significantly higher additional atypical features like atelectatic bands & subpleural curvilinear atelectasis (66%), followed by discrete nodules (42%) were associated with COVID 19 diagnosis in the absence of any known co-morbid conditions. We propose that imaging findings that have not been categorized under any of the existing four groups, be incorporated in either a mixed category or added to any of the existing groups, in the current imaging-based classification for COVID 19.

Key Words: Atypical, COVID 19, HRCT, GGO, RT-PCR

INTRODUCTION

Coronavirus infection has become a global concern since the outbreak of Severe Acute Respiratory Syndrome Coronavirus (SARS-COV-1) in 2002-2003.[1,2] and the Middle East Respiratory Syndrome Coronavirus (MERS-CoV) in 2012.[3,4] In late December 2019, an outbreak of pneumonia was reported in Wuhan, China caused by novel coronavirus 2019-nCoV, currently designated as a severe acute respiratory syndrome (SARS-COV-2) by the International Committee on Taxonomy of Viruses (ICTV).[5] The disease has now been officially named COVID 19 by World Health Organization. On January 7, 2020 a novel coronavirus has been identified as a causative agent by viral typing.[6]

Initially, it caused an outbreak of pneumonia in china and thereafter had spread globally with nearly 9 million confirmed cases and 470,000 deaths till June 23,2020.[7] With the growing global concerns about the COVID-19 outbreak, it necessitates a comprehensive understanding of the hallmark and/ or atypical imaging features for an early diagnosis. In a study by Simpson et al. in the year 2020 imaging findings were categorized into four groups: Typical, Atypical, Indeterminate and Negative for COVID 19.[8] It provides a set protocol that can reduce variation in

Corresponding Author:
Rohit Arora, Junior Resident, Department of Radio-Diagnosis, Kalinga Institute of Medical Sciences, Bhubaneswar, Odisha, India.
Telephone: +91-9718897648; E-mail: arorarohit0810@gmail.com

ISSN: 2231-2196 (Print) **ISSN:** 0975-5241 (Online)

Received: 05.03.2021 **Revised:** 09.04.2021 **Accepted:** 11.05.2021 **Published:** 11.06.2021

reporting. The primary findings on chest radiographs and CT is that of atypical pneumonia or organizing pneumonia.

Reverse transcriptase-polymerase chain reactions (RT-PCR), which serves as a gold standard, has a sensitivity of about 71 per cent,[9] while High-Resolution Computed Tomography (HRCT) Thorax appears to have a much higher sensitivity as analysed by Fang et al. who reported a 98 % sensitivity for the diagnosis of COVID-19.[10] RT PCR for COVID-19 takes about 2-3 days for the results to come and hence clinicians are dependent on accurate diagnostic imaging for isolation & specific management.[11]

In this study, we have attempted to analyse HRCT images of 1300 COVID-19 and HRCT positive patients and evaluated the prevalence of the atypical imaging features amongst our study group. In addition, imaging findings amongst the patients from this part of the country, which do not fit under any of the existing groups necessitated inclusion in a separate category. Hence, we propose a modification of the available criteria for categorizing COVID 19 based on imaging and incorporation of these imaging features.

MATERIALS AND METHODS

Patient population and study design

This is a prospective study conducted in Odisha COVID Hospital, KIMS, India.

1300 consecutive COVID positive (RT-PCR) patients without known co-morbid conditions with positive imaging features on HRCT Thorax were included in our study group.

Computerised Tomography (CT) Acquisition Technique

Chest CT acquisitions were obtained with the patients in the supine position during end inspiration. Evaluation is done with 64-slice CT Siemens Somatom go. Up having 2.2 cm stellar detector with Sinogram Affirmed Iterative Reconstruction (SAFIRE) software dedicated only to patients of COVID 19. The scan was performed with the following technical parameters tube voltage 100-120 V; tube current modulation 180-400 mAs; automated exposure control; collimation width 64 X 0.625 mm; interslice gap 0mm; reconstruction algorithm: iterative-based reconstruction. Reconstructions were obtained at a slice thickness of 1.25 mm.

The scanning range covered the area from the level of the thoracic inlet to the diaphragm.

Computerised Tomography (CT) Image Analysis

All the CT images were viewed by two Residents involved in the study, followed by two Senior Radiologists. Radiological findings were classified into three groups viz. Typical, Atypical and Indeterminate for COVID 19 (Table 1), similar to an earlier study by Simpson S et.al. Negative for COVID 19 pneumonia were excluded in our study population. All data were anonymized and collected in a shared database. In our study the following atypical features were considered for analysis:

Presence of

a) Soft tissue nodules
b) Pleural effusion or pleural thickening
c) Mediastinal or hilar lymphadenopathy (> 10mm in short axis diameter)
d) Isolated consolidation
e) Presence of atelectasis
f) Presence subpleural linear or curvilinear opacification
g) Underlying lung diseases like fibrosis, bronchiectasis changes or emphysema
h) Pleural effusion or pleural thickening, lymphadenopathy and pneumothorax or pneumo-mediastinum in addition to ground glass opacifications (GGO's).

The nodule is around or irregular opacity of less than 3 cm in diameter with sharp or ill-defined margins. They are classified as centrilobular or tree-in-bud and discrete nodules.[12] GGO represent filling of alveolar space with pus, oedema, haemorrhage or cells causing haziness with preserved broncho-vascular marking.[13,14] Consolidation refers to opacification of the alveolar space with the abutment of broncho-vascular markings.[15,16] Sub pleural lines (also known as pleural lines) refers to thin linear or curvilinear opacities, 1-3 mm in thickness, lying less than 1 cm from and parallel to the pleural surface.

RESULTS

1300 positive COVID-19 patients, with positive imaging findings were analysed. We found that 320 patients (24.6%) showed atypical imaging features, 860 patients (64.6%) were in the Typical and 140 (10.7%) were in the indeterminate category (Fig.1).

We found that of the 24.6% patients having atypical imaging findings on HRCT, Isolated lobar or segmental consolidation without associated GGO's was noted in 5.6% of patients, 42.8% had discrete pulmonary nodules which includes both centrilobular and tree-in-bud nodular patterns, 9.3% presented with mediastinal lymphadenopathy/ hilar lymphadenopathy. About 11.2% had pleural effusion and 1.2% demonstrated pneumothorax and pneumomediastinum. Linear or subsegmental atelectasis was noted in 66.2% of patients (Table 1).

About 86% of the patients showing atypical imaging features on HRCT belonged to the adult age group while 9% and 5% belonged to the elderly and paediatric age group respectively.

We also found the presence of GGOs in addition to discrete nodules in 73, hilar or mediastinal lymphadenopathy in 42, pneumothorax or pneumomediastinum in 1 and pleural effusion in 7 patients and about 212 patients showed linear or subsegmental atelectasis (Table 2), probably due to partly resolving pneumonia or early fibrosis.

DISCUSSION

Established guidelines are the need of the hour for a comprehensive understanding of Typical & atypical imaging features on CT, for an early diagnosis and effective patient management.

The commonest imaging findings noted on HRCT in our study population were multifocal GGO's of rounded morphology, GGO's with associated interlobular septal thickening termed as "crazy paving appearance" and GGO's associated with air space consolidation. There was the involvement of multiple lobes especially lower lobes with a peripheral distribution and basal zone predilection in the majority of the cases. Other features included halo-sign, reverse halo-sign, non-rounded or non-peripheral GGO's with or without consolidation lacking specific distribution, coarse linear or curvilinear opacities or fine subpleural reticulations, isolated consolidation without GGO, discrete small nodules (centrilobular or tree in bud), pleural effusion, pneumothorax/ pneumomediastinum, bronchiectasis changes and lymphadenopathy.

320 patients showed atypical imaging features which accounts for about 24.6 % of the total study sample. Atypical imaging features (Fig. 2) in this study group were, isolated lobar or segmental consolidation without GGO's in 18 patients, discrete pulmonary nodules, both centrilobular and tree-in-bud patterns in 137, hilar or mediastinal lymphadenopathy in 30, pleural effusion or pleural thickening in 36 and pneumothorax or pneumo-mediastinum in 4 patients. 212 patients showed linear or subsegmental atelectasis.

In a study by Federica Ciccarese et al., it was stated that 7 out of 211 (3.3%) COVID positive patients had atypical imaging features. However, 60 out of 249 (24 %) patients showed atypical imaging features who were negative on RT-PCR[17] indicating that these features have a more common association with a non-COVID aetiology. In another study by Sudhir Bhandari et al. on 80 COVID patients revealed that about 2.5% of patients had atypical imaging features on HRCT.[18] In another retrospective study on 96 suspected COVID patients by de Jaegere et al. (RSNA) found that amongst 45 RT-PCR positive patients, 2.5-5.3% showed atypical imaging features on HRCT.[19] This depicts a significantly higher prevalence of atypical imaging features in COVID 19 patients in our study sample, as compared to the previous studies. Hence it is felt that atypical imaging features may not be such an uncommon association in COVID 19, as previously conceptualized.

As per the presently available literature, the Chest CT severity score does not include certain atypical imaging features like pleural effusion, pneumothorax or pneumomediastinum and lymphadenopathy.[20] At present, atypical features on imaging is thought to be associated with non- COVID 19 aetiology, like Tuberculosis or other viral infections, aspiration pneumonia and metastasis.[21] But in our study we found an association of additional *atypical* imaging features in a significant number of RT-PCR positive patients, without any comorbidities like tuberculosis, chronic kidney diseases, hepatitis and immunocompromised conditions like HIV, Hepatitis B and patients on immunosuppressants. Hence images must be analysed meticulously in order not to overlook these features that will help in accurate CT staging, standardisation and enhance the diagnostic efficacy.

Atypical imaging features were most commonly seen in the adult age group and less commonly in the paediatric and elderly age groups in our study population. The probable cause of this adult involvement could be due to higher exposure to the infected population.

We also found that certain additional imaging findings were overlapping and were not categorized under any of the types i.e. Typical, Atypical, Indeterminate for COVID as per present imaging-based classification. These findings are as follows:

a) Unaccompanied ground glass opacifications and nodules
b) Ground glass opacifications and pleural effusion/ pleural thickening
c) Ground glass opacifications and pneumothorax/ pneumomediastinum
d) Ground glass opacifications and hilar/ mediastinal lymphadenopathy
e) Linear or Sub-segmental atelectasis

CONCLUSION

In our study group in this part of the country, the Typical features were 64.6%, indeterminate 10.7% and Atypical 24.6%. Significantly higher atypical features like atelectatic bands & subpleural curvilinear atelectasis (66%), followed by discrete nodules (42%) were more in favour of COVID 19 in absence of any other known co-morbid conditions like tuberculosis, chronic kidney diseases, hepatitis and immunocompromised conditions like HIV, Hep B and patients on immunosuppressants. It was noted that the prevalence of atypical features was more prevalent in the adult population.

We propose that the imaging findings found in our study, which have not been categorized under any of the four groups, need to be incorporated in either a mixed category

or any of the existing groups in the current imaging, based classification for COVID 19.

In this pandemic situation, all patients with respiratory tract infection, fever, dyspnoea & HRCT features of COVID, including these *atypical* features, may be subjected to RT PCR to rule out COVID 19. Faster diagnosis, early isolation to restrict the spread of the disease will help society at large, besides helping in specific management.

Conflict of Interest: Nil

Source of funding: Nil

Authors' contributions –

Arora R, Sen KK, Panda S, Mohanty SS, Goyal M, Dubey R.

Arora R - Primary and corresponding author is responsible for ensuring that the descriptions are accurate and agreed by all authors,

Sen **KK** – Guide for manuscript preparation,

Panda **S** and Mohanty **SS** had made substantial contributions to all of the following: (1) the conception and design of the radiological work; (2) the acquisition, analysis, and interpretation of radiological data; and (3) drafting the work and revising it

Goyal M and Dubey **R** had made substantial contributions to (1) acquisition, analysis, and interpretation of clinico-laboratory data and (2) drafting the work and revising it.

All authors approved the submitted version. All authors have agreed both to be personally accountable for the author's own contributions and to ensure that questions related to the accuracy or integrity of any part of the work, even ones in which the author was not personally involved, are appropriately investigated, resolved, and the resolution documented in the literature.

REFERENCES

1. Zhong NS, Zheng BJ, Li YM, Poon LL, Xie ZH, Chan KH, Li PH, Tan SY, Chang Q, Xie JP, Liu XQ et al. Epidemiology and cause of severe acute respiratory syndrome (SARS) in Guangdong, People's Rep of China, in February, 2003. The Lancet. 2003 Oct 25;362(9393):1353-8.
2. Drosten C, Günther S, Preiser W, Van Der Werf S, Brodt HR, Becker S, Rabenau H, Panning M, Kolesnikova L, Fouchier RA, Berger A et al. Identification of a novel coronavirus in patients with severe acute respiratory syndrome. NE J Med. 2003 May 15;348(20):1967-76.
3. Zaki AM, Van Boheemen S, Bestebroer TM, Osterhaus AD, Fouchier RA et al. Isolation of a novel coronavirus from a man with pneumonia in Saudi Arabia. NE J Med. 2012 Nov 8;367(19):1814-20.
4. Cauchemez S, Van Kerkhove MD, Riley S, Donnelly CA, Fraser C, Ferguson NM et al. Transmission scenarios for Middle East Respiratory Syndrome Coronavirus (MERS-CoV) and how to tell them apart. Eurosurveillance. 2013 Jun 13;18(24):20503.
5. Yang Q, Liu Q, Xu H, Lu H, Liu S, Li H et al. Imaging of coronavirus disease 2019: a Chinese expert consensus statement. Eur J Res. 2020 Apr 18:109008.
6. Chen Y, Liu Q, Guo D Ge XY, Li JL, Yang XL et al. Emerging coronaviruses: genome structure, replication, and pathogenesis. J Med Vir. 2020 Apr;92(4):418-23.
7. Nagpal P, Narayanasamy S, Vidholia A, Guo J, Shin KM, Lee CH, Hoffman EA et al. Imaging of COVID-19 pneumonia: Patterns, pathogenesis, and advances. Bri J Res. 2020 Sep 1;93(1113):20200538.
8. Simpson S, Kay FU, Abbara S, Bhalla S, Chung JH, Chung M, Henry TS, Kanne JP, Kligerman S, Ko JP, Litt H et al. RSNA expert consensus document on reporting chest CT findings related to COVID-19: endorsed by the society of thoracic Radiology, the ACR, and RSNA. Rad Card Imag. 2020 Mar 25;2(2):e200152.
9. Fang Y, Zhang H, Xie J, Lin M, Ying L, Pang P, Ji W et al. Sensitivity of chest CT for COVID-19: comparison to RT-PCR. Rad. 2020 Aug;296(2): E115-7.
10. Ai T, Yang Z, Hou H, Zhan C, Chen C, Lv W, Tao Q, Sun Z, Xia L et al. Correlation of chest CT and RT-PCR testing for coronavirus disease 2019 (COVID-19) in China: a report of 1014 cases. Rad. 2020 Aug;296(2): E32-40.
11. Yang Y, Yang M, Shen C, Wang F, Yuan J, Li J, Zhang M, Wang Z, Xing L, Wei J, Peng L et al. Laboratory diagnosis and monitoring the viral shedding of 2019-nCoV infections. MedRxiv. 2020 Jan 1.
12. MacMahon H, Naidich DP, Goo JM, Lee KS, Leung AN, Mayo JR, Mehta AC, Ohno Y, Powell CA, Prokop M, Rubin GD et al. Guidelines for the management of incidental pulmonary nodules detected on CT images: from the Fleischner Society 2017. Rad. 2017 Jul;284(1):228-43.
13. Lei J, Li J, Li X, Qi X et al. CT imaging of the 2019 novel coronavirus (2019-nCoV) pneumonia. Radiology. 2020 Apr;295(1):18.
14. Koo HJ, Lim S, Choe J, Choi SH, Sung H, Do KH et al. Radiographic and CT features of viral pneumonia. Radiogr. 2018 May;38(3):719-39.
15. Chung M, Bernheim A, Mei X, Zhang N, Huang M, Zeng X, Cui J, Xu W, Yang Y, Fayad ZA, Jacobi A et al. CT imaging features of 2019 novel coronavirus (2019-nCoV). Radiol. 2020 Apr;295(1):202-7.
16. Müller NL, Ooi GC, Khong PL, Zhou LJ, Tsang KW, Nicolaou S et al. High-resolution CT findings of severe acute respiratory syndrome at presentation and after admission. Ashi J Rad. 2004 Jan;182(1):39-44.
17. Ciccarese F, Coppola F, Spinelli D, Galletta GL, Lucidi V, Paccapelo A, De Benedittis C, Balacchi C, Golfieri R et al. Diagnostic accuracy of North America Expert Consensus Statement on reporting ct findings in patients with suspected COVID-19 infection: an Italian single-centre experience. Radiology. Cardioth Imag. 2020;2(4).
18. Bhandari S, Rankawat G, Bagarhatta M, Singh A, Gupta V, Sharma S, Sharma R et al. Clinico-Radiological Evaluation and Correlation of CT Chest Images with Progress of Disease in COVID-19 Patients. J Assoc Physic Ind. 2020 Jul 1;68(7):34-42.
19. De Jaegere TM, Krdzalic J, Fasen BA, Kwee RM et al. COVID-19 CT Investigators South-East Netherlands (CISEN) Study Group. Radiological Society of North America chest CT classification system for reporting COVID-19 pneumonia: interobserver variability and correlation with RT-PCR. Radiol Cardioth Imag. 2020;2(3):e200213.
20. Yang R, Li X, Liu H, Zhen Y, Zhang X, Xiong Q, Luo Y, Gao C, Zeng W et al. Chest CT severity score: an imaging tool for assessing severe COVID-19. Radiology: Cardioth Imag. 2020 Mar 30;2(2):e200047.

21. Ketai L, Paul NS, Ka-tak TW. Radiology of severe acute respiratory syndrome (SARS): the emerging pathologic-radiologic correlates of an emerging disease. J Thor Imag. 2006 Nov 1;21(4):276-83.

Table 1: Imaging findings on HRCT Thorax with atypical features for COVID-19 (n=320), as per available literature

Isolated Atypical Imaging Features	Patients (%)
Nodule	137/320 (42.8%)
Pleural effusion/ Pleural thickening	36/320 (11.2%)
Hilar/ Mediastinal lymphadenopathy	30/320 (9.3%)
Linear or Sub-segmental atelectasis	212/320 (66.2%)
Pneumothorax/ Pneumomediastinum	4/320 (1.2%)
Lobar or segmental consolidation	18/320 (5.6%)

Table 2: Imaging findings on HRCT Thorax not classified under current imaging based classification for COVID-19 (n=320)

Mixed Imaging Features	Patients (%)
Unaccompanied ground glass opacifications with nodules	73/320 (22.8%)
Ground glass opacifications with pleural effusion/ pleural thickening	7/320 (2.2%)
Ground glass opacifications with pneumothorax/ pneumomediastinum	2/320 (0.6%)
Ground glass opacifications with lymphadenopathy	42/320 (13.1%)
Linear subpleural opacities	212/320 (66.2%)

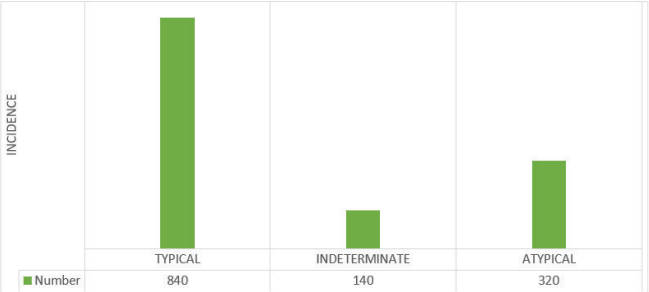

Figure 1: Different CT chest imaging patterns among the COVID-19 positive patients.

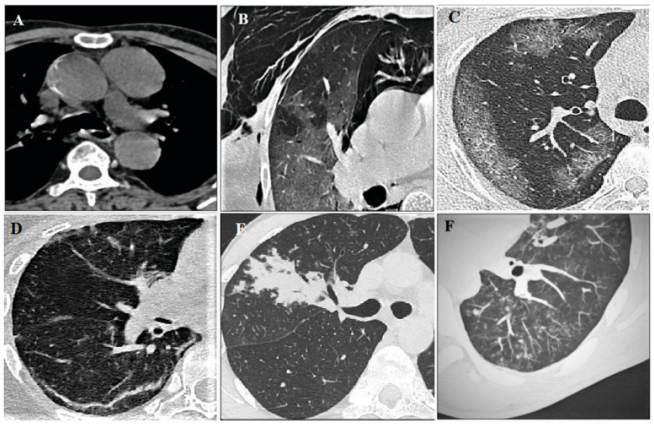

Figure 2: Axial section through HRCT chest demonstrating atypical imaging features. (A) Mediastinal lymphadenopathy; (B) Ground glass opacifications, pneumothorax, pneumomediastinum and subcutaneous emphysema; (C) Peripheral confluent ground glass opacifications; (D) Subpleural curvilinear opacifications; (E) Isolated segmental consolidation; (F) Tree-in bud nodules.