



# A DETAILED STUDY OF SEVERITY OF ANAEMIA AND ITS RELATION WITH THE GENDER OF THE PATIENTS (MALE OR FEMALE PATIENTS) WITH HOOKWORM INFECTION FOUND WHILE DOING ENDOSCOPY

**Govindarajalu Ganesan**

Associate Professor, Department of General Surgery, Aarupadai Veedu Medical College and Hospital, Puducherry - 607402.

## ABSTRACT

**Objective:** A detailed study was done to know about the severity of anaemia and its relation with the gender of the patients (male or female patients) with hookworm infection found in the duodenum while doing upper gastro intestinal endoscopy in our institute.

**Methods:** A study of 1259 patients who had undergone upper gastro-intestinal endoscopy for a period of 5 years from May 2009 to April 2014 was carried out in our institute in order to find out the severity of anaemia and its relation with the gender of the patients (male or female patients) with hookworm infection found in the duodenum while doing upper gastro intestinal endoscopy in our institute.

**Results:** 1. Out of these 1259 patients, 14 patients found to have hookworms in duodenum while doing upper gastro-intestinal endoscopy were taken into consideration for our study.

2. Out of these 14 patients with hookworms in duodenum, 9 patients had anaemia. Out of these 9 patients with anaemia, 2 patients were found to have severe anaemia, 1 patient had moderate anaemia and 6 patients had mild anaemia. Out of these 14 patients with hookworms in duodenum, 5 patients did not have anaemia.

3. Out of these 14 patients, 6 patients were men and 8 patients were women. Most of the male patients with hookworm infection did not have anaemia. But almost all the female patients with hookworm infection had anaemia. The few male patients with anaemia had only mild or moderate anaemia. Severe anaemia occurred only in the female patients and did not occur in any male patient.

**Conclusion:** Hence female patients with hookworm infection were more prone for anaemia than the male patients in our study.

**Key Words:** Grades of anaemia, Hookworm infection in duodenum, Upper gastro intestinal endoscopy

## INTRODUCTION

Anaemia is commonly reported to occur in hookworm infection (1 to 18). But so far detailed study was not done to know about the severity of anaemia and its relation with the gender of the patients (male or female patients) with hookworm infection found in the duodenum while doing upper gastro intestinal endoscopy. Hence a detailed study was done to know about the severity of anaemia and its relation with the gender of the patients (male or female patients) with hookworm infection found in the duodenum while doing upper gastro intestinal endoscopy in our institute.

## MATERIALS AND METHODS

This study was conducted in the department of general surgery, Aarupadai Veedu Medical College And Hospital, Puducherry. A study of 1259 patients who had undergone upper gastro-intestinal endoscopy in our institute for a period of 5 years from May 2009 to April 2014 was carried out in order to know about the various grades of anaemia [mild, moderate and severe anaemia] and its relation with the gender of the patients (male or female patients) with hookworm infection found in the duodenum while doing upper gastro intestinal endoscopy in our institute.

### Corresponding Author:

Govindarajalu Ganesan, Associate Professor, Department of General Surgery, Aarupadai Veedu Medical College and Hospital, Puducherry - 607402; E-mail: drgganesan@gmail.com

Received: 16.08.2015

Revised: 14.09.2015

Accepted: 20.10.2015

tinal endoscopy. Anaemia is defined as haemoglobin < 12g/dl or 12g% in women(19 to 26) and haemoglobin < 13g/dl or 13g% in men(25, 26). Mild anaemia is taken as haemoglobin 10to12g/dl or 10to12 g%, moderate anaemia is taken as haemoglobin 7to10g/dl or 7to10g% and severe anaemia is taken as haemoglobin <7g/dl or 7g%(27). The results were found as given below.

## RESULTS

1. Out of these 1259 patients, 14 patients found to have hookworms in duodenum while doing upper gastrointestinal endoscopy were taken into consideration for our study.
2. Out of these 14 patients with hookworms in duodenum, 2 patients were found to have severe anaemia[haemoglobin <7g/dl ], 1 patient had moderate anaemia[haemoglobin 7to10g/dl], 6 patients had mild anaemia[haemoglobin 10to12g/dl] and 5 patients did not have anaemia[haemoglobin >13g/dl or 13g% in men and haemoglobin > 12g/dl or 12g% in women].
3. Out of these 14 patients with hookworms in duodenum,6 patients were men and 8 patients were women. Most of the male patients with hookworm infection did not have anaemia. But almost all the female patients with hookworm infection had anaemia. The few male patients with anaemia had only mild or moderate anaemia. Severe anaemia occurred only in the female patients and did not occur in any male patient.

### MALE PATIENTS WITHOUT ANAEMIA

1. Out of the 6 male patients with hookworms in duodenum, 4 male patients did not have anaemia. All the 4 patients had haemoglobin >13g/dl or 13g%.
2. Hence majority of the male patients with hookworm infection did not have anaemia [67%] .
3. Single hookworm in duodenum seen in the male patient without anaemia[haemoglobin >13g/dl or 13g%] is shown in fig1.

### MALE PATIENTS WITH ANAEMIA

1. Out of the 6 male patients with hookworms in duodenum, only 2 male patients had anaemia[33%].
2. One male patient had only mild anaemia [haemoglobin 11.7g%].
3. The other male patient had moderate anaemia [haemoglobin 8.6g%].
4. None of the male patients had severe anaemia.
5. Hence male patients with hookworm infection were not much affected by anaemia in our study.

6. Single hookworm in duodenum seen in the male patient with mild anaemia [haemoglobin 11.7g%] is shown in fig 2.

### FEMALE PATIENTS WITHOUT ANAEMIA

Out of the 8 female patients with hookworms in duodenum,only one female patient did not have anaemia.

### FEMALE PATIENTS WITH ANAEMIA

1. All the remaining 7 female patients with hookworms in duodenum had anaemia.
2. Hence majority of the female patients with hookworm infection had anaemia[87.5%].
3. 5 female patients with hookworms in duodenum had mild anaemia[haemoglobin 11.7g%, 11.2g%, 11.2g%, 10.4g%, 10g%].
4. 2 female patients with hookworms in duodenum were found to have severe anaemia [haemoglobin<7g/dl or 7g %].
5. Hence female patients with hookworm infection were affected much by anaemia in our study.

### FEMALE PATIENTS WITH SEVERE ANAEMIA

1. Out of the 14 patients with hookworms in duodenum, only 2 patients had severe anaemia.
2. But both the patients with severe anaemia in our study were female patients.
3. Both the female patients with severe anaemia had very low haemoglobin.
4. One female patient with hookworms in duodenum had only haemoglobin 3.2g%.
5. The other female patient with hookworms in duodenum had only haemoglobin 2.1g%.
6. Severe anaemia occurred only in the female patients and did not occur in any male patient.
7. Multiple hookworms in duodenum seen in the female patient with severe anaemia [haemoglobin 3.2g%] is shown in fig 3.
8. Multiple hookworms in duodenum seen in the female patient with severe anaemia [haemoglobin 2.1g%] is shown in fig 4.

### SEVERE ANAEMIA AND GENDER OF THE PATIENTS

Both the patients with hookworms in duodenum with severe anaemia in our study were female patients. The world health organisation has also identified adolescent girls and women of child bearing age as high risk groups regarding the impact of hookworm disease(28).

## DISCUSSION

1. Out of the14 patients with hookworms in duodenum taken into consideration for our study, 5 patients with hookworms in duodenum did not have anaemia.

2. But out of the 5 patients with hookworms in duodenum without anaemia, 4 were male patients [80%] and only one was a female patient [20%].
3. Hence many male patients with hookworms in duodenum did not have anaemia in our study.
4. The few male patients with anaemia had only mild or moderate anaemia.
5. Out of the 8 female patients with hookworms in duodenum, 7 female patients had anaemia [87.5%] and only one female patient did not have anaemia [11.5%].
6. Hence many female patients with hookworms in duodenum had anaemia in our study.
7. Severe anaemia also occurred only in the female patients with hookworms in duodenum [haemoglobin 2.1g%, 3.2g%] and did not occur in any male patient with hookworms in duodenum.
8. Hence hookworm infection occurred mostly in the female patients and did not affect the male patients considerably in our study.

### CONCLUSION

1. Many male patients with hookworms in duodenum did not have anaemia in our study.
2. But many female patients with hookworms in duodenum had anaemia in our study.
3. Severe anaemia also occurred only in the female patients with hookworms in duodenum and did not occur in any male patient with hookworms in duodenum.
4. Hence female patients with hookworm infection were more prone for anaemia than the male patients in our study.

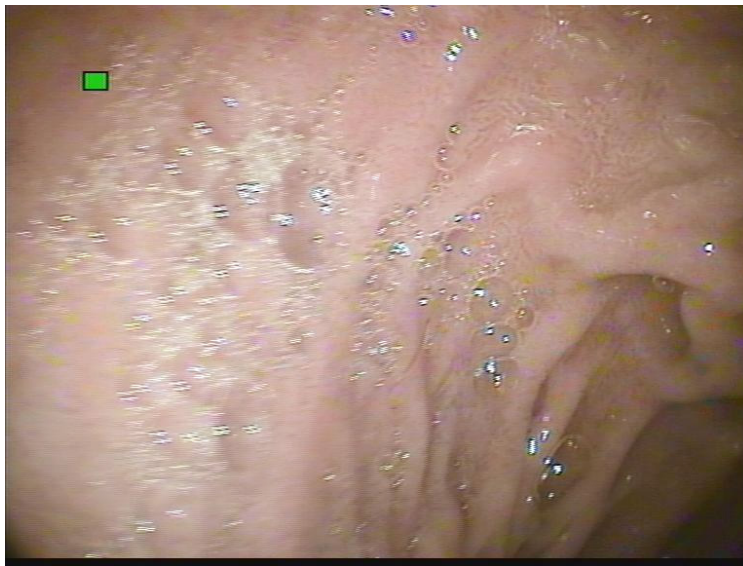### ACKNOWLEDGEMENT

The author acknowledges and sincerely thanks the staff nurse Prema for the immense help rendered to the author by her in the endoscopy section in the department of general surgery. The author sincerely thanks the staff nurses Nithya and Shenbaghaprabha who were assisting the author while doing endoscopy. The author acknowledges and sincerely thanks the staff nurse A.K. Selvi for the immense help rendered to the author by her while conducting this work. The author acknowledges the immense help received from the scholars whose articles are cited and included in references of this manuscript. The author is also grateful to authors / editors / publishers of all those articles, journals and books from where the literature for this article has been reviewed and discussed. The author is extremely grateful to IJCRR editorial board members and IJCRR team of reviewers who have helped to bring quality to this manuscript.

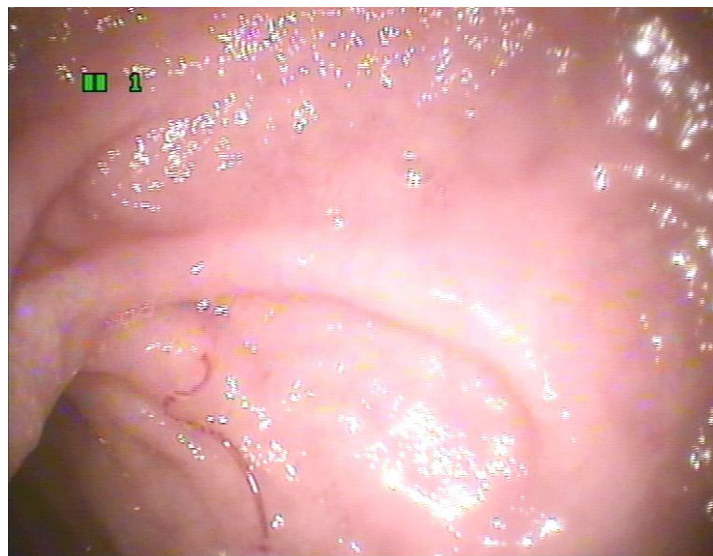
### REFERENCES

1. Hyun HJ, Kim EM, Park SY, Jung JO, Chai JY, Hong ST. A case of severe anemia by *Necator americanus* infection in Korea. *J Korean Med Sci*. 2010 Dec;25(12):1802-4.
2. Wu KL, Chuah SK, Hsu CC, Chiu KW, Chiu YC, Changchien CS. Endoscopic Diagnosis of Hookworm Disease of the Duodenum: A Case Report. *J Intern Med Taiwan* 2002;13:27-30.
3. Kuo YC, Chang CW, Chen CJ, Wang TE, Chang WH, Shih SC. Endoscopic Diagnosis of Hookworm Infection That Caused Anemia in an Elderly Person. *International Journal of Gerontology*. 2010 ; 4(4) : 199-201
4. Zaher, T. I., Emara, M. H., Darweish, E., Abdul-Fattah, M., Bihery, A. S., Refaey, M. M., and Radwan, M. I. Detection of Parasites During Upper Gastrointestinal Endoscopic Procedures. *Afro-Egypt J Infect Endem Dis* 2012; 2 (2): 62-68.
5. Basset D, Rullier P, Segalas F, Sasso M. Hookworm discovered in a patient presenting with severe iron-deficiency anemia *Med Trop (Mars)*. 2010 Apr;70(2):203-4
6. Lee T.-H., Yang J.-c., Lin J.-T., Lu S.-C. and Wang T.-H. Hookworm Infection Diagnosed by Upper Gastrointestinal Endoscopy: —Report of Two Cases with Review of the Literature—. *Digestive Endoscopy*, 1994 6(1): 66–72
7. Kato T, Kamoi R, Iida M, Kihara T. Endoscopic diagnosis of hookworm disease of the duodenum *J Clin Gastroenterol*. 1997 Mar;24(2):100-102
8. Anjum Saeed, Huma Arshad Cheema, Arshad Alvi, Hassan Suleman. Hookworm infestation in children presenting with malena -case series *Pak J Med Res Oct - Dec 2008;47(4) :98-100*
9. Li ZS1, Liao Z, Ye P, Wu RP. Dancing hookworm in the small bowel detected by capsule endoscopy: a synthesized video. *Endoscopy*. 2007 Feb;39 Suppl 1:E97. Epub 2007 Apr 18.
10. Kalli TI, Karamanolis G, Triantafyllou K. Hookworm infection detected by capsule endoscopy in a young man with iron deficiency. *Clin Gastroenterol Hepatol*. 2011 Apr;9(4):e33
11. Chen JM1, Zhang XM, Wang LJ, Chen Y, Du Q, Cai JT. Overt gastrointestinal bleeding because of hookworm infection. *Asian Pac J Trop Med*. 2012 Apr;5(4):331-2.
12. A Rodríguez, E Pozo, R Fernández, J Amo, T Nozal. Hookworm disease as a cause of iron deficiency anemia in the prison population *Rev Esp Sanid Penit* 2013; 15: 63-65
13. Cedrón-Cheng H, Ortiz C. Hookworm Infestation Diagnosed by Capsule Endoscopy. *J Gastroint Dig Syst* 2011 S1:003. doi: 10.4172/2161-069X.S1-003
14. Yan SL, Chu YC. Hookworm infestation of the small intestine *Endoscopy* 2007; 39: E162±163
15. Chao CC1, Ray ML. Education and imaging. Gastrointestinal: Hookworm diagnosed by capsule endoscopy. *J Gastroenterol Hepatol*. 2006 Nov;21(11):1754.
16. Christodoulou, D. K., Sigounas, D. E., Katsanos, K. H., Dimos, G., and Tsianos, E. V.. Small bowel parasitosis as cause of obscure gastrointestinal bleeding diagnosed by capsule endoscopy. *World journal of gastrointestinal endoscopy*, 2(11), 2010: 369.
17. Genta RM, Woods KL. Endoscopic diagnosis of hookworm infection. *Gastrointest Endosc* 1991 July;37(4):476-8
18. Nakagawa Y, Nagai T, Okawara H, Nakashima H, Tasaki T, Soma W, et al. Comparison of magnified endoscopic images of *Ancylostoma duodenale* (hookworm) and *Anisakis simplex*. *Endoscopy* 2009;41(Suppl. 2):E189
19. Kabir, Y., Shahjalal, H. M., Saleh, F., and Obaid, W. Dietary pattern, nutritional status, anaemia and anaemia-related knowledge in urban adolescent college girls of Bangladesh. *JPMA. The Journal of the Pakistan Medical Association*, 2010; 60(8), 633.

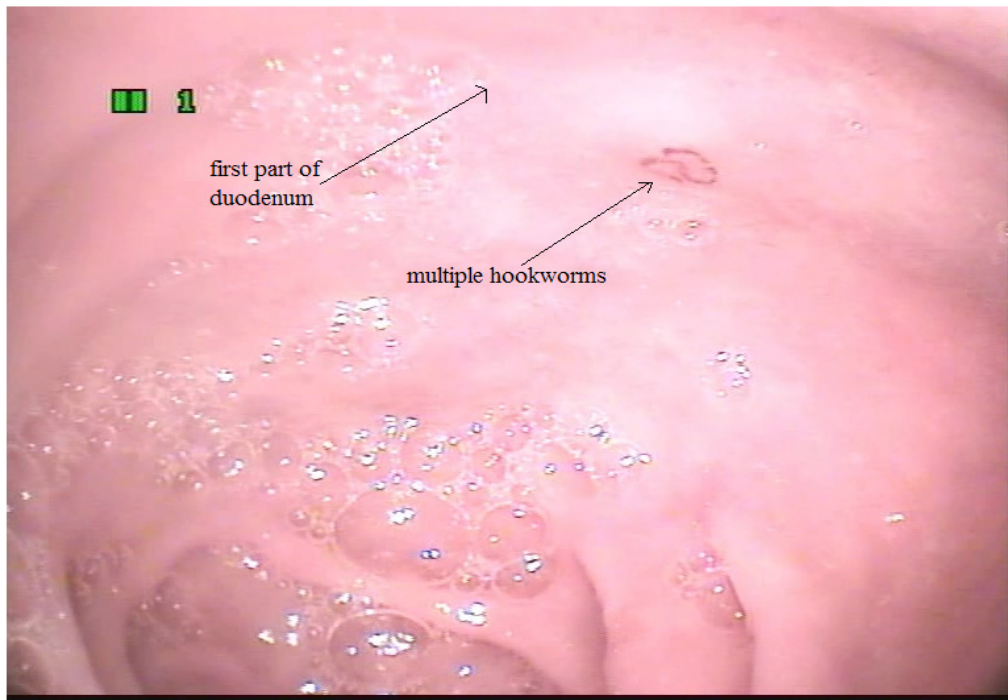
20. Ahmed, F., Khan, M. R., Islam, M., Kabir, I., and Fuchs, G. J.. Anaemia and iron deficiency among adolescent schoolgirls in peri-urban Bangladesh. *European journal of clinical nutrition*, 2000 ;54(9), 678-683.
21. Ahmed F1, Khan MR, Karim R, Taj S, Hyderi T, Faruque MO, Margetts BM, Jackson AA. Serum retinol and biochemical measures of iron status in adolescent schoolgirls in urban Bangladesh. *Eur J Clin Nutr*. 1996 Jun;50(6):346-51.
22. Foo, L. H., Khor, G. L., Tee, E. S., and Prabakaran, D.. Iron status and dietary iron intake of adolescents from a rural community in Sabah, Malaysia. *Asia Pacific journal of clinical nutrition*, 2004 ;13(1), 48-55.
23. Chandyo, R. K., Strand, T. A., Ulvik, R. J., Adhikari, R. K., Ulak, M., Dixit, H., and Sommerfelt, H. Prevalence of iron deficiency and anemia among healthy women of reproductive age in Bhaktapur, Nepal. *European journal of clinical nutrition*, 2007;61(2), 262-269.
24. Sarita Modi, Bose Sukhwant Study of iron status in female medical students Indian Journal of Basic and Applied Medical Research; March 2013: Issue-6, Vol.-2, P. 518-526
25. Sikosana, P. L., Bhebhe, S., and Katuli, S.. A prevalence survey of iron deficiency and iron deficiency anaemia in pregnant and lactating women, adult males and pre-school children in Zimbabwe. *Central African Journal of Medicine*, 1998;44(12), 297-304.
26. WHO. Iron deficiency anaemia: assessment, prevention, and control. a guide for programme managers. Geneva, Switzerland: World Health Organization, 2001. (WHO/NHD/01.3.)
27. Hyder, S. M. Z., Persson, L. Å., Chowdhury, M., Lönnerdal, B. O., and Ekström, E. C.. Anaemia and iron deficiency during pregnancy in rural Bangladesh. *Public health nutrition*, 2004 ; 7(08), 1065-1070.
28. Crompton DW, Whitehead RR. Hookworm infections and human iron metabolism *Parasitology*. 1993;107 Suppl:S137-45.



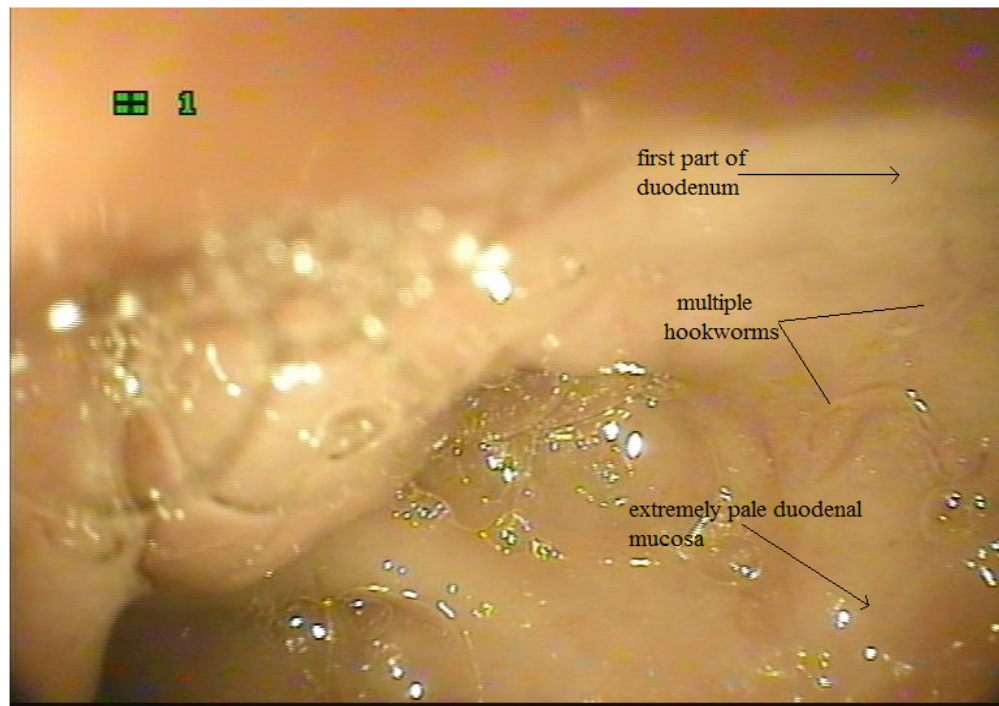
**Figure 1:** Single hookworm in duodenum in a male patient without anaemia [haemoglobin >13g/dl]



**Figure 2:** Single hookworm in duodenum in the male patient with mild anaemia [haemoglobin 11.7g%]



**Figure 3:** Multiple hookworms in duodenum in the female patient with severe anaemia [haemoglobin 3.2g%]



**Figure 4:** Multiple hookworms in duodenum in the female patient with severe anaemia [haemoglobin 2.1g%]