



IJCRR

Section: Healthcare

 Sci. Journal
 Impact Factor
 4.016

ANGIOLIPOMA CAUSING COLOCOLIC INTUSSUSCEPTION: A RARE CASE REPORT

M. Ganesan, A. Ajay Raja, A. Avinash

Department of General Surgery, Meenakshi Medical College and Research and Institute, Kanchipuram, India.

ABSTRACT

Intussusception is defined as the telescoping of proximal segment of intestine into a distal segment of intestine. Intussusception is usually idiopathic, without an obvious anatomic lead point.

Colocolic intussusception due to angioliipoma is very uncommon on the left side of the colon. The disease is diagnosed often late following disease progression which is attributed to its indolent course and its non specific symptomology.

This cases is presented for its rarity.

Key Words: Intussusception, Colocolic intususception, Angioliipoma

INTRODUCTION

Intussusception can cause a tear in the bowel , gangrene of bowel tissue and infection. Intussusception is the commonest cause of intestinal obstruction in children age less than 3. In older children, the incidence of the a pathological lead point is up to 12%, where meckel's diverticulum is found to be most common lead point for intussusceptions.

However, other causes such as intestinal polyps, inflamed appendix, submucosal hemorrhage, foreign body, ectopic pancreatic or gastric tissue.

We report two case in which Colocolic intussusceptions due to angioliipoma.

CASE REPORT

A 55 years old man presented with lower abdominal pain for two days with no episode of vomiting, constipation and bleeding per rectum with no previous history of similar complaints. The patient was not tachycardic with normal blood investigations. A radiogram of the erect abdomen was taken which showed a few air fluid levels with no pneumoperitoneum. An early ultrasonography of abdomen revealed telescoping of bowel within bowel in the left iliac fossa with a well defined echogenic focal lesion in its distal portion. CECT scans revealed submucosal lipoma causing colo-colic intussusceptions in the left side of the colon. A diagnosis of colo-colic intussusception was made and the patient

was managed initially by nil per oral, intravenous fluids and antibiotics and with Ryles tube aspiration and a decision of emergency laparotomy was made and proceeded.

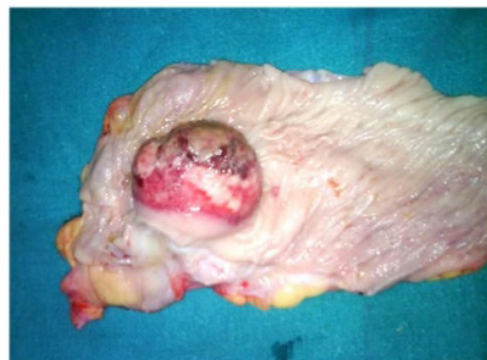

Figure 1: Angioliipoma as Lead Point in Colocolic Intususception Intra Operatively.

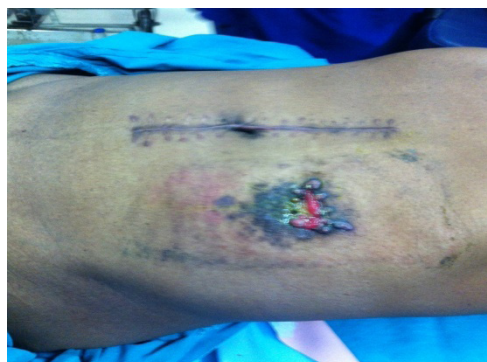

Figure 2: Post Operative Picture of Colostomy.

Corresponding Author:

A. Ajay Raja, Department of General Surgery, Meenakshi Medical College and Research and Institute, Kanchipuram, India.
 E-mail: drajayraja005@gmail.com

Received: 29.01.2016

Revised: 19.02.2016

Accepted: 13.03.2016

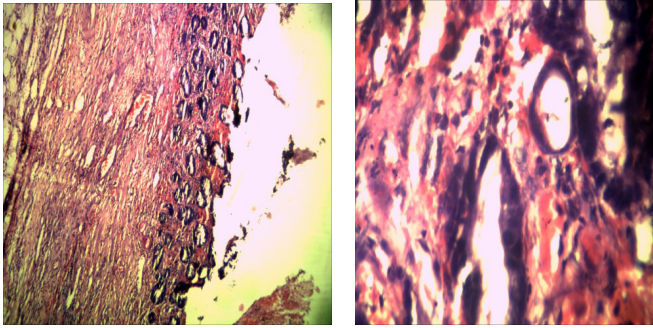


Figure 3: Histology of Colocolic Intussusception Due to Angiolipoma.

At laprotomy the surgical team found the presence of colocolic intussusception in the descending colon involving about 8cm of the descending colon and the lead point was found to be a submucosal lipoma of size 10x8x4cm. The intussusception was reduced and a descending colon of about 10-12cm was found to be gangrenous and that segment of the gangrenous part was resected and the proximal loop of the descending colon was brought out as a colostomy and the distal loop was sutured with anterior abdominal wall with 3-0vicryl. The colostomy was fixed with the skin by 2-0silk. Histopathological examination of the specimen revealed findings consistent with angiolipoma. The patient had an expected postoperative period. Oral feeds were resumed after 3 days. The patient was discharged after suture removal and asked to come after six weeks. After six weeks patient was prepared for colostomy closure, distal loop of colon is anastomised with colostomy end to end anastomosis done and patient had an expected postoperative period. the patient was discharged and asked to review after one week.

DISCUSSION

Intussusception is a process in which a segment of intestine invaginates into the adjoining intestinal lumen, causing bowel obstruction. Intussusception also cuts off the blood supply to the part of the intestine that's affected.

Intussusception can lead to a tear in the bowel (perforation), infection and death of bowel tissue. Intussusception is the most common cause of intestinal obstruction in children younger than 3. Intussusception is rare in adults. Most cases of adult intussusception are the result of an underlying medical condition, such as a tumor. In this article, we reviewed the cases of Colocolic intussusception due to angiolipoma is very uncommon on the left side of the colon. This case highlights the fact that a high suspicion of a intussusceptions should be kept in mind in dealing with patient with intestinal obstruction.

CONCLUSION :

It is telescoping or invaginating of one portion (segment) of bowel into the adjacent segment. Intussusception are two types antegrade and retrograde. In elderly intussusceptions colocolic is most common type, apex is formed usually by growth. It can be ileo-colic (most common type 75%), colocolic, ileoileocolic, colocolic. Intussusception is common in weaning period of a child (common in males), between the period of 6-9 months. It is the commonest cause of intestinal obstruction in children of 6-18 months age.

ACKNOWLEDGEMENT

The author acknowledges the immense help received from the scholars whose articles are cited and included in references of this manuscript. The authors are also grateful to the authors/editors/publishers of all those articles, journals and books from where the literature for this article has been reviewed and discussed.

REFERENCES

1. <http://www.mayoclinic.org/diseases-conditions/intussusception/home/ovc-20166951>
2. Toso C, Erne M, Lenzlinger PM, Schmid JF, Büchel H, Melcher G, Morel P (2005). "Intussusception as a cause of bowel obstruction in adults" (PDF). *Swiss Med Wkly* 135 (5-6): 87-90. PMID 15729613.
3. Gayer G, Zissin R, Apter S, Papa M, Hertz M (2002). "Pictorial review: adult intussusception--a CT diagnosis". *Br J Radiol* 75 (890): 185-90. PMID 11893645
4. Bailey & Love's 25th Edition/ Chapter no 66/ acute intussusceptions.
5. Park NH, Park SI, Park CS, Lee EJ, Kim MS, Ryu JA, Bae JM (2007). "Ultrasonographic findings of small bowel intussusception, focusing on differentiation from ileocolic intussusception". *Br J Radiol* 80 (958): 798-802. doi:10.1259/bjr/61246651. ISSN 0007-1285. PMID 17875595
6. Cera, SM (2008). "Intestinal Intussusception". *Clin Colon Rectal Surg* 21 (2): 106-13. doi:10.1055/s-2008-1075859. ISSN 1531-0043. PMID 20011406
7. Bai YZ, Chen H, Wang WL. A special type of postoperative intussusception: ileoileal intussusception after surgical reduction of ileocolic intussusception in infants and children. *J Pediatr Surg*. 2009 Apr. 44(4):755-8.
8. Haas EM, Etter el, Ellis S, et al: Adult intussusceptions. *Am J Surg* 186:75,2003
9. Fraser JD, Aguayo P, Ho B, et al. Laparoscopic management of intussusception in pediatric patients. *J Laparoendosc Adv Surg Tech A*. 2009 Aug. 19(4):563-5.
10. Niramis R, Watanatittan S, Kruatrachue A, et al. Management of recurrent intussusception: nonoperative or operative reduction?. *J Pediatr Surg*. 2010 Nov. 45(11):2175-80.