



IJCRR

Section: Healthcare

Sci. Journal Impact

Factor: 6.1 (2018)

ICV: 90.90 (2018)



Copyright@IJCRR

An Institutional Based Study on Imaging Conundrum of Newly Diagnosed Coronavirus Disease 2019 (COVID-19) – A Retrospective Analysis in India Population

Vandana Goel¹, B. R. Goyal², Archana Mathur³, Gyan Chand³, Vineet Marwaha¹, Anil Dhar⁴

¹Senior Consultant, Department of Radiology, Max Super Specialty Hospital, Patparganj, Delhi, India; ²Director & Head, Department of Radiology, Max Super Specialty Hospital, Patparganj, Delhi, India; ³Principal Consultant, Department of Radiology, Max Super Specialty Hospital, Patparganj, Delhi, India; ⁴Consultant, Department of Neurosurgery, Max Super Specialty Hospital, Patparganj, Delhi, India.

ABSTRACT

Introduction: Coronavirus disease-2019 (COVID-19) was announced as a pandemic by the World Health Organization (WHO) on March 11, 2020. According to a WHO report on COVID-19, the disease has nospecific manifestation and the patient's presentation can range from completely asymptomatic to severe pneumonia and death.

Objective: To retrospectively characterize and interpret the spectrum of chest computed tomography (CT) imaging features of Coronavirus disease - 19 (COVID-19) in infected Indian population and to correlate CT total severity score with clinical classification and study extra-pulmonary manifestation of Corona-virus disease 2019 (COVID-19).

Methods: A retrospective single-centre study was conducted on patients with COVID-19 from May 10, 2020, to July 13, 2020, in tertiary care Max super specialty hospital, Delhi, India. A total of 532 patients either laboratory-confirmed or strongly suspected of having COVID-19 underwent CT chest and their imaging features were analyzed and interpreted in detail and studied for extra-pulmonary manifestation of COVID-19. The consistency of observers was evaluated for CT total severity score (TSS) and TSS was compared with clinical classification.

Result: This study included 532 patients, 10 patients were excluded from the study. Among a total of 522 patients in the study, 362 (69.3%) were males and 160 (30.7%) were females with a mean age of 52.75 years (range 14-88). According to the clinical subtype classification there were mild 17 (3.3%), common 355 (68.0%), severe 105 (20.1%) and critical 45 (8.6%) cases. 57 (10.9%) patients died and 37 (7.08%) patients showed extra-pulmonary manifestation of COVID-19. There were 17 patients with normal CT chest. Only 2 cases had unilateral lung disease and the rest of 503 cases showed bilateral lung involvement with multiple opacities and multiple lobe involvement. Diffuse lung involvement i.e. white lung noted in 10 cases and none of the patient had single lesion. Opacities on CT imaging tended to be both peripheral and central in most cases, followed by purely peripheral and rarely are with the purely central distribution. According to CT attenuation of opacity, Ground glass opacity (GGO), and the mixture of Ground glass opacity & consolidative opacities and consolidative opacities was the dominant abnormality founded almost in all cases. Perilesional or intralesional, thickened small vessel was observed in almost all cases. Accompanying signs were crazy paving (40.6%), reverse halo sign (10.9%), subpleural lines (47.9%), air bronchogram (28.4%), bronchiectasis (18.6%), pleural effusion (5.6%) and mediastinal lymphadenopathy (4.8%). Follow up scanning was obtained in 28 cases, showed no change in 2 cases, turned better in 12 cases, and became worse in 14 cases on follow up imaging studies.

Conclusions: The typical pattern of COVID-19 pneumonia in Delhi, India, was ground glass opacity in the form of pure ground glass opacity, ground glass opacity with superimposed crazy paving pattern or Ground glass opacity admixed with consolidation with intralesional vascular enlargement were the most dominant lung parenchymal abnormalities with the peripheral and posterior distribution encountered in most of the cases. In the short term follow-up, more patients had disease progression rather than absorption.

Proportion of patients [17 (3.2%)] with normal CT chest in laboratory-confirmed COVID-19 was relatively low; hence chest CT may play a complementary role in the early detection of COVID-19 pneumonia and could be regarded as a diagnostic standard of COVID-19. COVID-19 is progressive viral pneumonia with broad spectrum of clinical manifestations and can also present with extra-pulmonary manifestations.

Key Words: COVID-19, WHO, GGO, TSS, CT

Corresponding Author:

Dr. Vandana Goel, Senior Consultant, Department of Radiology, Max Super Specialty Hospital, Patparganj, Delhi, India.

ISSN: 2231-2196 (Print)

ISSN: 0975-5241 (Online)

Received: 22.07.2020

Revised: 20.08.2020

Accepted: 18.09.2020

Published: 20.10.2020

INTRODUCTION

An outbreak of severe acute respiratory syndrome Coronavirus 2 (SARS-CoV-2) infection was reported in Wuhan in December 2019, Hubei Province, China¹. Coronavirus disease-2019 (COVID-19) was announced as a pandemic by the World Health Organization (WHO) on March 11, 2020. According to a WHO report on COVID-19, the disease has no specific manifestation and the patients presentation can range from completely asymptomatic to severe pneumonia and death². However, some symptoms have been reported to be more common in COVID-19 patients, which are fever (98%), cough (76%), and myalgia or fatigue (44%)³. The keys to control COVID-19 are early detection, early isolation, and early treatment. Reverse transcription-polymerase chain reaction (RT-PCR) is a highly specific test and the gold standard for the diagnosis of COVID-19. However, the variable sensitivity of RT-PCR and its lengthy turnaround time (24–48 h⁴ underscore the need for a complementary diagnostic approach^{5,6,7,8}. Besides, multiple negative RT-PCR test results may be needed to rule out the disease in patients with a high clinical suspicion of COVID-19⁹. It was also reported that false-negative RT-PCR was not rare and, in these patients, initial chest CT might present abnormal findings indicating COVID-19¹⁰. Therefore, some experts suggested that chest CT could be regarded as a diagnostic standard of COVID-19.

Xie X, et al conducted a study to address the importance of chest computed tomography (CT) examination in COVID-19 patients with false-negative RT-PCR results^{5,8} and reported the CT sensitivity as 98%⁶

CT examination is of great significance in diagnosing COVID-19 and monitoring disease progression and evaluating therapeutic efficacy.^{11,12,13}

The latest research studies described the characteristic imaging manifestations of COVID-19, including ground-glass opacities (GGO) (57 to 88%), bilateral involvement (76 to 88%), and peripheral distribution (33 to 85%)^{14,15,16,17}

Bilateral distribution of ground-glass opacities (GGO) with or without consolidation in posterior and peripheral lungs was the cardinal hallmark of COVID-19^{14,18}

Although COVID-19 is principally a respiratory illness and pulmonary manifestations are main presentations of the disease, SARS-CoV-2 infection is not limited to the respiratory system and other organs can also be affected. COVID-19 is a progressive viral pneumonia with broad spectrum of clinical manifestations and also present with extra-pulmonary manifestations. Our clinical experience and the emerging literature suggest that the hematologic, cardiovascular, renal,

gastrointestinal and hepatobiliary, endocrinologic, neurologic, ophthalmologic, and dermatologic systems can all be affected¹⁹.

Therefore, with a comprehensive review of published studies and the experience of COVID-19 imaging interpretation in the frontline, we aim to review the typical and relatively atypical CT manifestations of COVID-19 in a pictorial fashion and help radiologists to familiarize with these possible imaging features of COVID-19 and Extra-pulmonary manifestations of Coronavirus infections

MATERIAL AND METHODS

This retrospective study was approved by the Review Committee and Ethics Committee of our institution. Written informed consent was waived since the study had no risk, and would not adversely affect the subject's right and welfare.

This single-center retrospective, study was conducted on patients with COVID-19 from May 10, 2020, to July 13, 2020, in tertiary care Max super specialty hospital, Delhi, India. A total of 532 patients either laboratory-confirmed or strongly suspected of having COVID-19 underwent CT chest. Inclusion criteria were (a) fever, sore throat and respiratory symptoms, such as cough and dyspnea; (b) mild respiratory symptoms and close contact with person with confirmed COVID-19; and (c) a previously positive reverse transcription–polymerase chain reaction (RT-PCR) result. Exclusion criteria were (a) case of known malignancy; and (b) incomplete clinical data.

10 patients were excluded, so among a total of 522 patients in the study, 364 were males and 158 were females with a mean age of 45 years (range 19 -88). Five radiologists with an experience of more than 15 years independently reviewed CT images and their imaging features were analyzed and interpreted in detail. In case of discrepant assessment results between the radiologists, images were reviewed, and a consensus was established.

Fig No 1 shows: CT scans were assessed for: (1) distribution: peripheral or peribronchovascular; (2) density: ground-glass opacities (Fig.1A), mixed ground-glass opacities (Fig.1B), or consolidation (Fig.1C); (3) thickened small vessels within opacity (Fig.1D); (4) internal structures: presence of air bronchogram; crazy paving (Fig.1E), reverse halo sign (Fig.1F), subpleural lines (Fig.1G) and bronchiectasis (Fig.1F); (4) number of lobes affected by ground-glass or consolidative opacities; (5) presence of pleural effusion; and (6) presence of thoracic lymphadenopathy (defined as lymph node size of ≥ 10 mm in short-axis dimension).

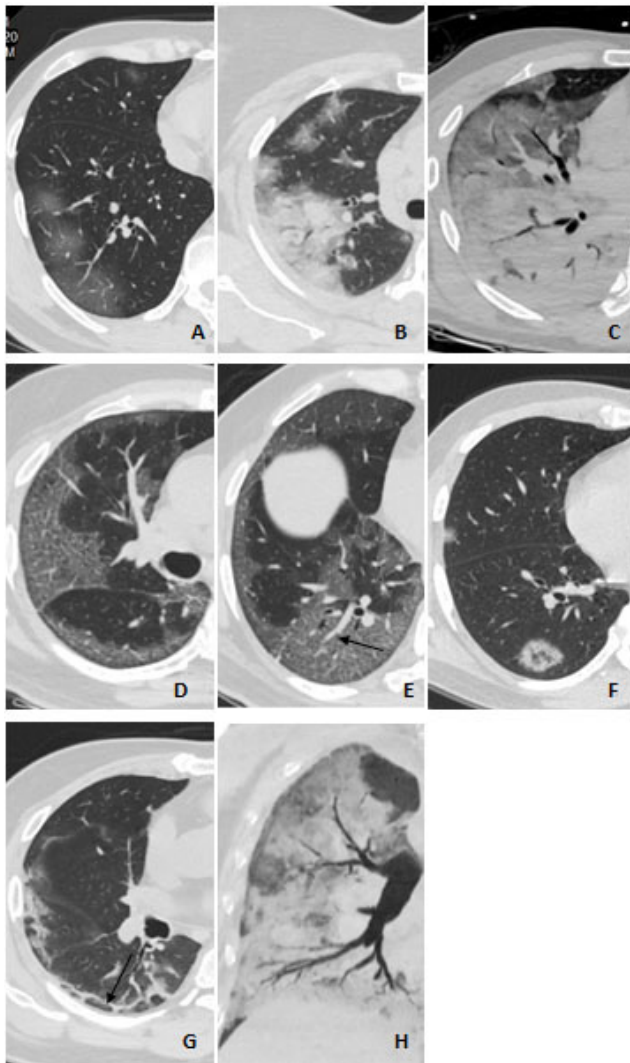


Figure 1: Non-contrast axial chest CT images showing various opacities – Fig.1A pure ground-glass opacity, Fig.1B mixed ground-glass opacities, Fig.1C consolidation Fig.1D crazy paving; Fig.1E thickened small vessels within opacity (black arrow); Fig.1F Reverse halo sign; Fig.1G subpleural lines(black arrow) and Fig.1H Minimum-intensity-projection showing bronchiectasis

Ground-glass opacification was defined as increased lung attenuation with preservation of bronchial and vascular margins and consolidation was defined as opacification with obscuration of margins of vessels and airway walls²⁰. A semi-quantitative scoring system - CT visual quantitative evaluation based on summing up the acute lung inflammatory lesions involving each lobe, scored as 0 – (0%), 1 – (1-25%), 2 – (26 – 50%), 3 – (51 – 75%), 4 –(76 – 100%). The total severity score (TSS) was calculated by summing the five lobe scores.¹⁴

Clinical classification

All cases were divided into four groups –based on the Diagnosis and Treatment Plan of COVID -19 issued by the

National Health Commission (7th ed.)²¹ Mild type – mild clinical symptoms without pneumonia on imaging.

Common type – fever, respiratory tract and other symptoms with pneumonia on imaging

Severe type – respiratory distress, respiratory rate >30 times/min: in resting state, oxygen saturation <93%, PaO₂/FiO₂<300MMHG

Critical type –respiratory failure requiring mechanical ventilation, shock and other organ failure requiring ICU monitoring and treatment

The consistency of observers was evaluated for CT total severity score (TSS) and TSS was compared with clinical classification

Statistical analysis

SPSS 17.0 (IBM Corp.) software was used for statistical analysis, including descriptive statistics. Continuous data conforming to normal distribution expressed by mean ± standard deviation; those not confirmed (median, P25, p75) were listed. The intragroup correlation coefficient (ICC) was used to test the consistency of TSS scores of observers, ICC values < 0.4, 0.4~0.75, and > 0.75 represent poor, moderate, and good repeatability, respectively. The distribution balance of involved lobes and the number of involved lobes in different clinical types were compared by t-test and ANOVA. *p*-value less than 0.05 was considered statistically significant

RESULT

Demographic and Clinical characteristics

Among a total of 522 patients in the study, 362 (69.3%) were males and 160 (30.7%) were females with a mean age of 52.75 years (range 14 -88). According to the clinical classification there were 17 (3.3%) mild, 355 (68.0%) common, 105 (20.1%) severe and 45 (8.6%) critical cases. 57 (10.9%) patients died and 37 (7.08%) patients showed extra-pulmonary manifestation of COVID -19. The demographic data for all patients are shown in Table 1.

Table 1: Showing demographics, Clinical characteristics for COVID-19 infected patients

| | Number | Percentage |
|---------------------|--------|------------|
| Sex | | |
| Female | 160 | 30.7 |
| Male | 362 | 69.3 |
| Co-morbidity | 299 | 57.3 |
| Fever | 425 | 81.4 |
| Cough | 366 | 70.1 |
| Fatigue | 147 | 28.2 |

Table 1: (Continued)

| | Number | Percentage |
|--------------------------|--------|------------|
| Sore Throat | 57 | 10.9 |
| Dyspnea | 295 | 56.6 |
| Gastrointestinal symptom | 115 | 22.1 |
| Clinical Classification | | |
| Mild | 17 | 3.3 |
| Common | 355 | 68.0 |
| Severe | 105 | 20.1 |
| Critical | 45 | 8.6 |

Flow chart depicting the result of reverse transcription–polymerase chain reaction (RT-PCR) and chest CT in symptomatic patients.

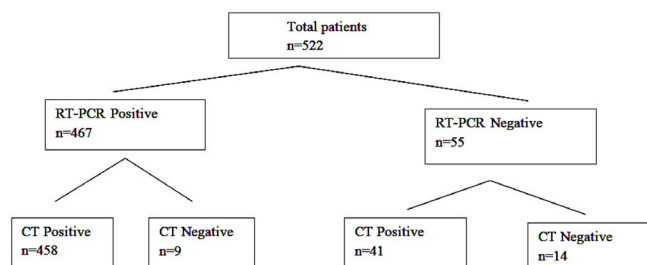


Table 2: Diagnostic performance of chest CT for COVID-19 infection with RT-PCR as the Reference Standard

| Statistics | TP | TN | FP | FN | Sensitivity | Specificity | PPV | NPV | Accuracy |
|------------|-----|----|----|----|--------------|-------------|--------------|------------|--------------|
| Findings | 458 | 14 | 41 | 9 | 458/467 (98) | 14/55 (25) | 458/499 (91) | 14/23 (60) | 472/522 (90) |

Note:- Data in parentheses are percentages, TP =true positive, TN = true negative, FP = false positive, FN = false negative, PPV = positive predictive value, NNV = negative predictive value, RT-PCR = reverse transcription polymerase chain rection

Table 3: Number and percentage (%) of patients with specific diagnostic features on CT images

| Characteristic | Number |
|------------------------|-------------|
| Opacity | |
| Ground glass | 483 (93.2%) |
| Mixed | 353 (67.6%) |
| Consolidation | 230 (44.1%) |
| Distribution | |
| Both | 325 (62.3%) |
| Peripheral | 166 (31.8%) |
| Central | 11 (2.1%) |
| Lesion characteristics | |

Table 3: (Continued)

| Characteristic | Number |
|--------------------------------|-------------|
| Subpleural Lines | 250 (47.9%) |
| Air Bronchoragm | 148 (28.4%) |
| Reverse Halo sign | 57 (10.9%) |
| Crazy Paving | 212 (40.6%) |
| Thickened small vessels within | 353 (67.6%) |
| Bronchiectasis | 97 (18.6%) |
| Lymph Node | 25 (4.8%) |
| Pleural Effusion | 29 (5.6%) |
| Number of involved lobes | |
| 0 | 17 (33%) |
| 1 | 14 (2.7%) |
| 2 | 32 (6.1%) |
| 3 | 15 (2.9%) |
| 4 | 34 (6.3%) |
| 5 | 410 (78.5%) |

Imaging findings of CT chest

Of the 522 patients, 467(89%) had positive RT-PCR results and 499(95%) had positive CT findings. Detailed results are reported in Table 2. With RT-PCR serving as the reference standard, sensitivity, specificity and accuracy of CT for COVID -19 pneumonia were 98%, 25% and 90% respectively. Only small proportion of patients [9 (1.9%)] with RT-PCR positive, had normal CT chest. Only 2 (0.38%) cases had unilateral lung disease (Fig 2), the rest of 503(96.3%) cases had bilateral lung disease with multiple opacities involving multiple lobes.

Multiple opacities involving all 5 pulmonary lobes were seen in the majority 410 (78.5%) of cases. Only small cases in the study had 1 lobe [14 cases (2.6%)], 2 lobes [32 cases (6.1%)], 3 lobes [15 cases (2.8%)] and 4 lobes [34 cases (6.5%)] involvement. Diffuse lung involvement i.e. white lung (Fig 3) was noted in 10 (1.9%) cases and none of the patients showed a single lesion. Common type and severe-critical type can both involve 5 lobes, but the severe-critical type had a higher incidence than the common type. Opacities on CT imaging tended to be both peripheral and central in a location (Fig 4) in most of the [325 (62.3%)] cases, followed by purely peripheral (Fig 5) [166 (31.8%)] and [11 (2.1%)] are with the purely central distribution(Fig 6).

According to CT attenuation of opacity, Ground glass opacity [483 (93.2%)], the mixture of Ground glass opacity & consolidative opacities [353 (67.6%)] and consolidative opacities [230 (44.1%)] were the dominant abnormality founded almost in all cases. Perilesional or intralesional thickened small vessel was observed in 353 (67.6%) cases.

Accompanying signs observed were, crazy paving 212 (40.6%), reverse halo sign in 57 (10.9%), subpleural lines in 250 (47.9%), air bronchogram in 148 (28.4%), and bronchiectasis in 97 (18.6%) patients. Pleural effusion was seen in 29 (5.6%) and most of them occurred in severe cases. Mediastinal lymphadenopathy was noted in very few 25 (4.8%) cases. Follow up scans was performed in 28 cases, showed no change in 2 cases, improvement in 12 cases, and worsening in 14 cases on follow up imaging studies.

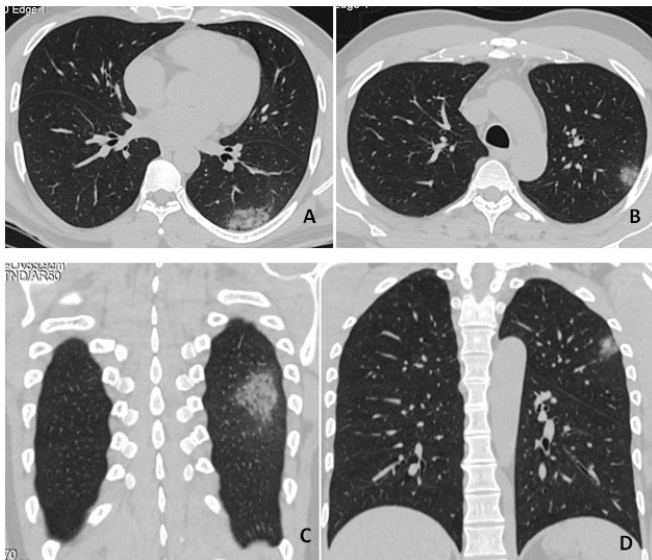


Figure 2: Non-contrast Axial (A&B) and Coronal (C&D) Chest CT images in a 38-year old COVID-19 positive male. Two oval ground glass opacities with some peripheral consolidation unilaterally in left lung with CT severity score 2/20.

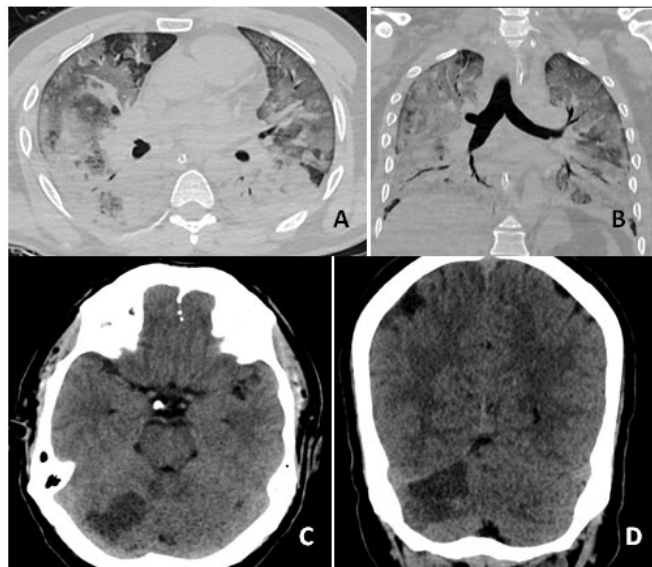


Figure 3: Non-contrast axial (A) and coronal (B) chest CT images of a 43-year old male COVID-19 positive, showing diffuse ground glass opacities with admixed areas of consolidation in both lungs ("white lung") with CT severity score 20/20.

Non-contrast axial (C) and coronal (B) head CT images of same patient, showing wedge-shaped hypodense area in right cerebellum suggestive of infarct -An extra-pulmonary neurological manifestation of COVID-19.

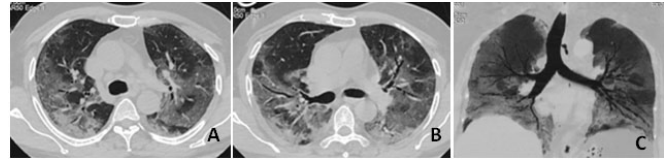


Figure 4: Non-contrast axial (A & B) chest CT images in 58-year old male COVID-19 positive patient, showing multiple confluent ground-glass with superimposed crazy paving admixed with patchy areas of consolidation in the central and peripheral portion of both lungs with posterior distribution. Minimum-intensity-projection (C) image demonstrate bronchiectasis with mild bronchial irregularity.

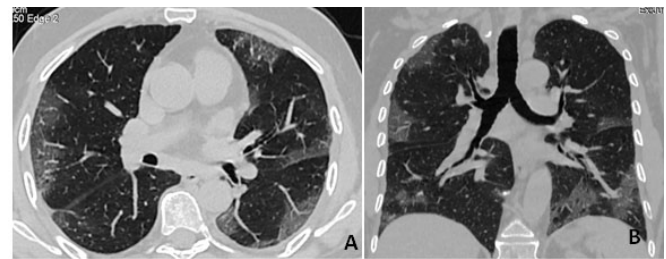


Figure 5: Non-contrast axial (A) and coronal (B) chest CT images in 73-year old male COVID-19 positive patient, showing multifocal ground-glass opacities with interlobular septal thickening presenting as a "crazy paving" pattern and accompanied with thickened small vessels in peripheral sub pleural region of both lungs.

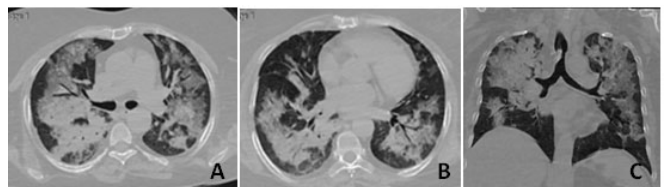


Figure 6: Non-contrast axial (A & B) and coronal (C) chest CT images in 52-year old female COVID-19 positive patient, showing centrally distributed diffuse ground glass opacities with superimposed crazy paving, admixed with patchy areas of consolidation with air bronchogram in both lungs with relative sparing of lung bases and peripheral subpleural region.

Table 4: Comparison of CT total severity score and clinical classification

| | Mild | Common | Severe | Critical |
|------------------|-------|--------|--------|----------|
| n | 17 | 355 | 105 | 45 |
| Mean | 0.00 | 6.12 | 10.20 | 14.16 |
| Median | 0.00 | 5.00 | 10.00 | 15.00 |
| Mode | 0 | 5 | 7 | 18 |
| Std. Deviation | 0.000 | 3.086 | 3.722 | 4.062 |
| Minimum | 0 | 1 | 4 | 5 |
| Maximum | 0 | 18 | 20 | 20 |
| 25th Percentiles | 0.00 | 5.00 | 7.00 | 11.00 |
| 50th Percentiles | 0.00 | 5.00 | 10.00 | 15.00 |
| 75th Percentiles | 0.00 | 7.00 | 12.00 | 17.50 |

Table 5A: Comparison of affected pulmonary lobes on CT and clinical classification

| Number of involved pulmonary lobes on CT | Clinical Severity | | | | Total |
|--|-------------------|--------------|--------------|-------------|---------------|
| | Mild | Common | Severe | Critical | |
| 0 | 17 100.0% | 0 0.0% | 0 0.0% | 0 0.0% | 17 100.0% |
| 1 | 0 0.0% | 14 100.0% | 0 0.0% | 0 0.0% | 14 100.0% |
| 2 | 0 0.0% | 32 100.0% | 0 0.0% | 0 0.0% | 32 100.0% |
| 3 | 0 0.0% | 15 100.0% | 0 0.0% | 0 0.0% | 15 100.0% |
| 4 | 0 0.0% | 25 75.8% | 6 18.2% | 2 6.1% | 33 100.0% |
| 5 | 0 0.0% | 269 65.4% | 99 24.1% | 43 10.5% | 411 100.0% |
| Total | 17 3.3% | 355 67.9% | 105 20.2% | 45 8.6% | 522 100.0% |

Independent t-Test: for Clinical Sub-classification, mild-common were grouped together and severe-critical were grouped together. Then these two groups were used for this analysis.

Table 5B: Comparison of affected pulmonary lobes on CT and clinical classification

| Clinical Sub-classification | Group Statistics | | | |
|-----------------------------|------------------|------|----------------|-----------------|
| | n | Mean | Std. Deviation | Std. Error Mean |
| Severe -critical | 150 | 4.95 | .225 | .018 |
| Mild-Common | 372 | 4.21 | 1.463 | .076 |

Comparison of CT visual quantitative evaluation and clinical classification

The number of involved pulmonary lobe on CT in different clinical types is shown in Table 5 (a,b,c,d,e,f). The score of mild type was 0, while the common type was 1–18 (median 5, 25th Percentiles 5, 75th Percentiles 7), the severe type was 4–20 (median 10, 25th Percentiles 7, 75th Percentiles 12) and the critical type was 5–20 (median 15, 25th Percentiles 11, 75th Percentiles 17.5). Since P-value is less than 0.05, the mean number of involved pulmonary lobes on CT is significantly higher in the severe-critical group as compared to the mild-common group.

There was a statistically significant difference in the average number of involved pulmonary lobes on CT between Clinical Sub-classification groups as determined by one-way ANOVA ($F(3,517) = 133.201, P < 0.001$). The number of involved pulmonary lobes on CT was surely very different in mild cases. A Tukey post hoc test revealed that the mean number involved pulmonary lobes on CT were statistically significantly lower in the common group compared with severe and critical groups. The difference between severe and critical was not statistically significant.

Inter-observer consistency of CT visual quantitative evaluation

The consistency test results of CT visual quantitative analysis of radiologists showed good repeatability with ICC 0.976 (95% confidence interval 0.962–0.985).

Interval changes in CT imaging in follow-up

Follow up was obtained in 28 cases, a second follow-up scan in 5 patients, and a third follow-up scan in 1 patient. During the first follow-up, 15 patients showed a radiographic improvement, 11 patients showed initial progression and 2 patients showed no change.

During the second follow-up in 5 patients, 1 patient showed improvement /resolution, 2 patients showed progression, and no change was seen in 2 cases. Third follow-up in 1 patient showed radiographic improvement.

Patients with improved radiographic appearance showed gradually absorbed opacities and sub-pleural fibrous stripes?

appearance compared with the first follow- CT scan (Fig 7). Patients with further progression showed an increasing number of ground-glass opacities and consolidation on follow-up scans (Fig 8).

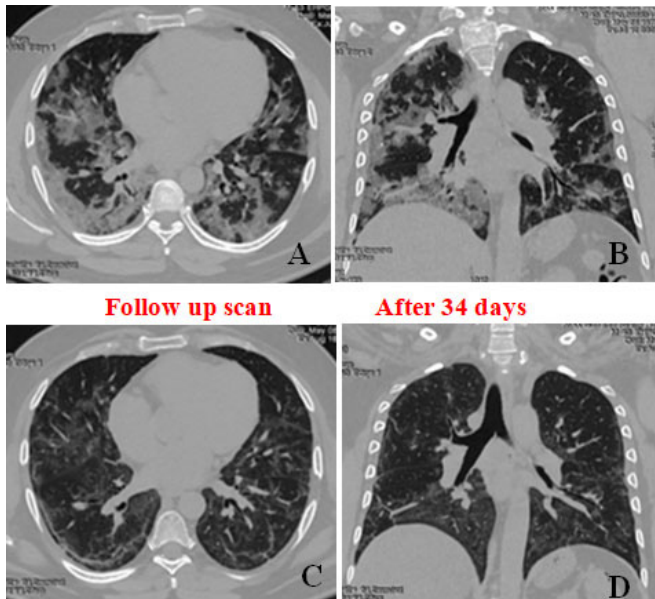


Figure 7: Initial and follow up CT images in 43 year old male with COVID-19 pneumonia. Axial (A) and coronal (B) CT images demonstrate bilateral ground-glass opacities admixed with patchy areas of consolidation in the central and peripheral portions of the lungs. Axial (C) and coronal (D) CT images obtained after 34 days demonstrate gradually absorbed ground glass opacities with presence of subpleural fibrous stripes suggestive of dynamic resolution –Absorptive stage.

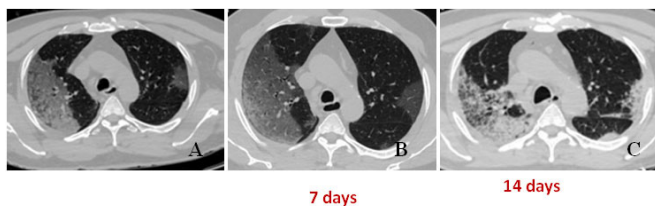


Figure 8: Fig 13 Initial and follow up CT images in 58-year old male COVID-19 positive patient. Axial (A) CT image showing peripheral ground-glass opacities with superimposed intralobular reticulations resulting in crazy paving in both lungs. 1st follow up Axial (B) CT image obtained after 7 days demonstrate mild increase in extent of opacity. 2nd follow up Axial (C) CT image obtained after 14 days demonstrate ground glass opacities admixed with areas of consolidation suggestive of temporal progression -Peak stage

The extra-pulmonary manifestation of COVID -19

Although COVID-19 is principally a respiratory illness, COVID-19 infection is not limited to the respiratory sys-

tem and other organs can also be affected and can involve hematologic, cardiovascular, renal, gastrointestinal and hepatobiliary, endocrinologic, neurologic, ophthalmologic, and dermatologic systems. In our study 37 (7.08%) patients showed extra-pulmonary manifestation of COVID -19. Neurological involvement was seen in 13 cases, presenting with infarct in 7 cases (Fig 9 and 10)), encephalopathy in 4 cases, subarachnoid hemorrhage in 1 case(Fig 11), and seizure in 1case. The gastrointestinal manifestation was seen in 6 cases, in the form of enteritis in 4 cases, acute pancreatitis in 1 case and sub-acute intestinal obstruction in 1 case. In our study, there were 15 (2.87%) cases of COVID-19 with gastrointestinal manifestation as the only presentation of the disease without respiratory abnormalities. Pulmonary embolism was seen in 3cases (Fig12), deep venous thrombosis in 7 cases, myocarditis in 2 cases, myocardial infarction in 1 case, renal dysfunction in 4 cases, and dermatitis in 1 case.

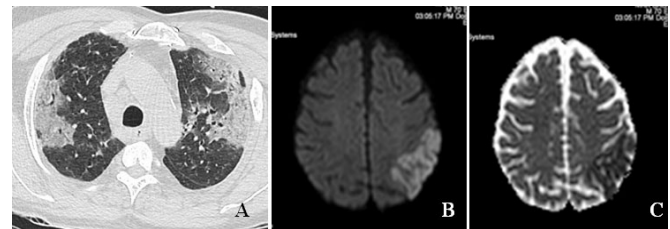


Figure 9: A 70-year-old male COVID-19 positive patient. Non-contrast axial (A) chest CT image demonstrates bilateral ground glass opacities, which are admixed with patchy consolidation areas. MR Axial DW (B) & ADC (C) brain images of same patient showing restricted diffusion in left posterior high parietal lobe – acute infarct.

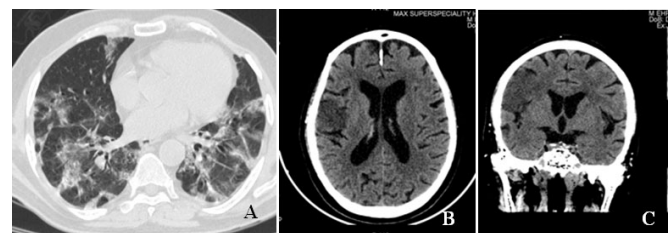


Figure 10: Unenhanced chest CT axial (A) image of 62-year-old man with bilateral ground glass opacities, admixed with fibrotic strips in the central and peripheral portions of the lung due to COVID-19 pneumonia. Axial (B) and coronal (C) CT head images of same patient shows wedge shaped hypo dense area involving both grey and white matter in right frontal and adjoining right perisylvian region - acute infarct.

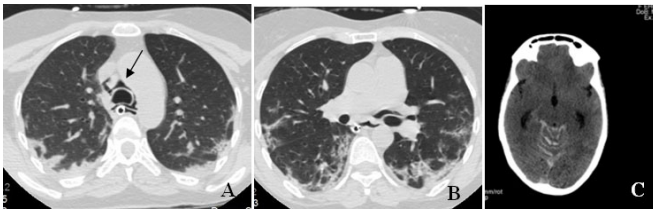


Figure 11: Unenhanced chest CT axial (A & B) images of an 50-year-old woman showing bilateral distribution of ground glass opacities, admixed with linear consolidation and fibrotic strips in posterior and peripheral lower lobes with pneumomediastinum (arrow) due to COVID-19 pneumonia. Axial (C) unenhanced CT head image of same patient shows subarachnoid haemorrhages in cerebellar folia and basal cistern.

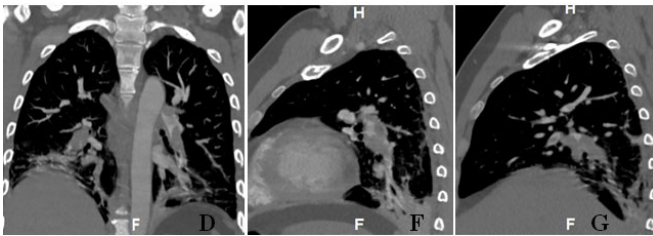
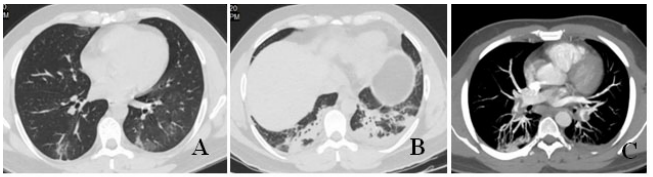


Figure 12: Initial and follow-up chest CT images in a 37-year-old man with COVID-19 pneumonia. An unenhanced initial chest CT axial (A) image shows bilateral peripheral ground glass in the dorsal segment of lower lobes. Contrast enhanced CT pulmonary angiography performed after 12 days – axial (B) demonstrate linear consolidation typical for an organizing pneumonia. Axial (C), coronal (D) and sagittal (E & F) CT pulmonary angiography images shows a filling defect within distal right and left main pulmonary arteries and extending into right and left lower lobe pulmonary arteries consistent with occlusive thrombus.

DISCUSSION

COVID-19 is a novel infectious disease that causes inflammation in the respiratory system. It is a highly contagious disease and spreads rapidly. The keys to control COVID-19 are early detection, early isolation, and early treatment. Reverse transcription-polymerase chain reaction (RT-PCR) is a highly specific test and the gold standard for the diagnosis of COVID-19. However, the variable sensitivity of RT-PCR and its lengthy turnaround time (24–48 h⁴) underscore the need for a complementary diagnostic approach.^{5,6,7,8}

To date, the majority of studies evaluating the role of chest CT in Coronavirus disease 2019 (COVID-19) pneumonia were conducted on patients in china. In our study 50 (9.5%)

patients showed discordant findings between CT chest and RT-PCR results. In most of these cases (41), the CT chest findings were suspicious of COVID-19, while the RT-PCR were negative. In the majority of these, the diagnosis at discharge was a pulmonary infection and out of these, 14 patients were having history of close contact with RT-PCR positive Covid-19 patient and 1 patient was positive for COVID-19 IgG Antibodies. Only small proportion of patients [9 (1.9%)] with RT-PCR positive, had normal CT chest.

With RT-PCR serving as the reference standard, sensitivity, specificity and accuracy of CT for COVID-19 pneumonia were 98%, 20% and 90% respectively. The diagnostic performance of chest CT in our study was in accordance with study conducted by Ai et al who reported a sensitivity of 97%, specificity of 25% and an accuracy of 68% in patients from Wuhan, China.⁷

Recent studies addressed the importance of chest computed tomography (CT) examination in COVID-19 patients with false-negative RT-PCR results^{5,8} and reported the CT sensitivity as 98%⁶. Our imaging features are in accordance with the previous studies reported in the literature^{14,22,23,24} of viral pneumonia. In our study, opacities on CT imaging showed multiple opacities with multilobe involvement in both lungs and opacities tended to be both peripheral and central in a location in most of the 325 (62.3%) cases followed by purely peripheral 166 (31.8%) and 11 (2.1%) are with the purely central distribution. According to CT attenuation of opacity, Ground glass opacity 483 (93.2%), the mixture of Ground glass opacity & consolidative opacities 353 (67.6%) and consolidative opacities 230 (44.1%) was the dominant abnormality founded almost in all cases. Perilesional or intralesional thickened small vessel was observed in 353 (67.6%) cases. Accompanying signs such as crazy paving 212 (40.6%), reverse halo sign 57 (10.9%), subpleural lines 250 (47.9%), air bronchogram 148 (28.4%), and bronchiectasis 97 (18.6%) were noted. Pleural effusion was seen in 29 (5.6%) and most of them occurred in severe cases. Only 2 (0.38%) cases had unilateral lung disease and none of the patients showed a single lesion.

In our study we used Minimum-intensity projection (MinIP) images –that are multiplanar slab images produced by displaying only the lowest attenuation value encountered along a ray cast through an object toward the viewer's eye. Bronchial dilatation and bronchus architectural distortion better depicted on Minimum-intensity-projection CT images as shown in fig

Semi-quantitative scoring system - CT visual quantitative evaluation based on summing up the acute lung inflammatory lesions involving each lobe, done by Mei X et al¹⁴. We used the same method to quantify pulmonary inflammation and correlate to the clinical classifications.

The score of mild type was 0, while the common type was 1–18 (median 5, 25th Percentiles 5, 75th Percentiles 7), the severe type was 4–20 (median 10, 25th Percentiles 7, 75th Percentiles 12) and the critical type was 5–20 (median 15, 25th Percentiles 11, 75th Percentiles 17.50). Simultaneous involvement of all five lobes was observed in 411 (78.7%) cases. Since P-value is less than 0.05, the mean number of involved pulmonary lobes on CT is significantly higher in the severe-critical group as compared to the mild-common group. A higher percentage of diseased lungs with higher CT severity scores was observed in patients with severe disease requiring ICU admission.

According to WHO reports the overall fatality rate for COVID-19 is estimated at 2.3 %²⁵, but the fatality rate has varied among studies from 1.4% to 4.3%^{26, 18}

Factors associated with an elevated case fatality rate included associated co-morbidities,²⁶ male sex, higher age, baseline diagnosis of severe pneumonia, and delay in diagnosis²⁵. In our case series, the overall mortality rate was 10.9% (57 patients) and most of them 78.9% (45 patients) had associated co-morbidity and had higher CT severity score. CT severity score more than 10 noted in 42 cases and less than 5 only in 3 cases.

SARS-CoV-2 infection is not limited to the respiratory system and other organs can also be affected. Emerging literature suggest that the hematologic, cardiovascular, renal, gastrointestinal and hepatobiliary, endocrinologic, neurologic, ophthalmologic, and dermatologic systems can all be affected.²³

In accordance with emerging literature, Extra-pulmonary manifestation of COVID-19 in our study was 7.08 % (37 patients) with Neurological involvement in 13 cases, presenting with Infarct in 7 cases (Figs), Encephalopathy in 4 cases, Subarachnoid hemorrhage in 1 case, and seizure in 1 case. The gastrointestinal manifestation was seen in 6 cases, in the form of enteritis in 4 cases, acute pancreatitis in 1 case and sub-acute intestinal obstruction in 1 case. In our study, there were 15 (2.87%) cases of COVID-19 with gastrointestinal manifestation as the only presentation of the disease without respiratory abnormalities. Pulmonary embolism was seen in 3 cases (Figs). Deep venous thrombosis in 7 cases, Myocarditis in 2 cases, Myocardial infarction in 1 case, Renal dysfunction in 4 cases, and Dermatitis in 1 case.

In view of broad spectrum of clinical manifestations and the increasing worldwide burden of the disease, there is an urgent need to rapidly scale up the diagnostic capacity to detect COVID-19 and its complications.

CONCLUSION

COVID-19 may present a varied clinical picture, such as asymptomatic carriage, with or without associated pneumo-

nia, and with or without several extra-pulmonary manifestations.

The typical pattern of COVID-19 pneumonia in Delhi, India, was ground glass opacity in the form of pure ground glass opacity, ground glass opacity with superimposed crazy paving pattern or Ground glass opacity admixed with consolidation with intralesional vascular enlargement was the most dominant lung parenchymal abnormality with the peripheral and posterior distribution encountered in most of the cases.

In the short term follow-up, more patients had disease progression than absorption

Only small proportion, 1.9% (9 patients) with RT-PCR positive, had normal CT chest hence chest CT may play a complimentary role in the early detection of COVID-19 and could be regarded as a diagnostic standard of COVID-19.

COVID-19 is a progressive viral pneumonia with broad spectrum of clinical manifestations and also present with extra-pulmonary features. In our study we have attempted to summarize the manifestations of COVID-19 and extra-pulmonary manifestation in many organs with the goal of consolidating knowledge to address the current pandemic.

LIMITATION

Selection bias as imaging was performed in all symptomatic cases regardless of the severity of illness

In our study mainly focused on initial or baseline imaging. Follow-up CT scans were only obtained for 28 of the 522 patients and thus the full range of disease appearance may not be represented.

No children are included in this study. Whether children may be less likely to become infected or, if infected, display milder symptoms is an important question to be addressed in future studies.

All studies were taken from Chinese studies; hence further studies in other countries are needed to corroborate these findings.

And lastly, Further studies are needed to elaborate extra-pulmonary manifestations of COVID-19.

Acknowledgment

Authors acknowledge the immense help received from the scholars whose articles are cited and included in references to this manuscript. The authors are also grateful to authors / editors / publishers of all those articles, journals, and books from which the literature for this article has been reviewed and discussed.

Conflict of interest: Nil

Source of Funding: Nil

REFERENCES

- Zhu N, Zhang D, Wang W. (2020) A novel coronavirus from patients with pneumonia in China, 2019. *N Engl J Med* 382:727–733]
- WHO Report of the WHO-China joint mission on coronavirus disease 2019 (COVID-19) 2020. <http://who.int/docs/default-source/coronaviruse/who-china-joint-mission-on-covid-19-final-report.pdf>
- Huang C, Wang Y, Li X (2020) Clinical features of patients infected with 2019 novel coronavirus in Wuhan, China. *Lancet* 395:497-506
- Hare S, Rodrigues J, Nair A, Robinson G (2020) Lessons from the frontline of the covid-19 outbreak. In: *BMJ Opin.* <https://blogs.bmj.com/bmj/2020/03/20/lessons-from-the-frontline-of-the-covid-19-outbreak/>. Accessed 28 Mar 2020
- Xie X, Zhong Z, Zhao W et al. (2020) Chest CT for typical 2019-nCoV pneumonia: relationship to negative RT-PCR testing. *Radiology* 200343. <https://doi.org/10.1148/radiol.2020200343>
- Fang Y, Zhang H, Xie J et al. (2020) Sensitivity of chest CT for COVID-19: comparison to RT-PCR. *Radiology* 200432. <https://doi.org/10.1148/radiol.2020200432>
- Ai T, Yang Z, Hou H et al. (2020) Correlation of chest CT and RT-PCR testing in coronavirus disease 2019 (COVID-19) in China: a report of 1014 cases. *Radiology* 200642. <https://doi.org/10.1148/radiol.2020200642>.
- Huang P, Liu T, Huang L et al. (2020) Use of chest CT in combination with negative RT-PCR assay for the 2019 novel coronavirus but high clinical suspicion. *Radiology* 295:22-23. <https://doi.org/10.1148/radiol.2020200330>
- Kanne JP, Little BP, Chung JH et al. (2020) Essentials for radiologists on COVID-19: an update—radiology scientific expert panel. *Radiology* 200527. <https://doi.org/10.1148/radiol.2020200527>.
- Chan JF, Yuan SF, Kok KH et al. (2020) A familial cluster of pneumonia associated with the 2019 novel coronavirus indicating person-to-person transmission: a study of a family cluster. *Lancet.* [https://doi.org/10.1016/S0140-6736\(20\)30154-9](https://doi.org/10.1016/S0140-6736(20)30154-9)].
- Pan Y, Guan H (2020) Imaging changes in patients with 2019-nCov. *Eur Radiol.* <https://doi.org/10.1007/s00330-020-06713-z>.
- Pan Y, Guan H, Zhou S et al. (2020) Initial CT findings and temporal changes in patients with the novel coronavirus pneumonia (2019-nCoV): a study of 63 patients in Wuhan, China. *Eur Radiol.* <https://doi.org/10.1007/s00330-020-06731-x> .
- Kim H (2020) Outbreak of novel coronavirus (COVID-19): what is the role of radiologists? *Eur Radiol.* <https://doi.org/10.1007/s00330-020-06748-2>
- Chung M, Bernheim A, Mei X et al. (2020) CT imaging features of 2019 novel coronavirus (2019-nCoV). *Radiology.* <https://doi.org/10.1148/radiol.2020200230>
- Song F, Shi N, Shan F et al. (2020) Emerging coronavirus 2019-nCoV pneumonia. *Radiology.* <https://doi.org/10.1148/radiol.2020200274>
- Kanne JP (2020) Chest CT findings in 2019 novel coronavirus (2019-nCoV) infections from Wuhan, China: key points for the radiologist. *Radiology.* <https://doi.org/10.1148/radiol.2020200241>
- Lei J, Li J, Li X, Qi X (2020) CT imaging of the 2019 novel coronavirus (2019-nCoV) pneumonia. *Radiology.* <https://doi.org/10.1148/radiol.2020200236>
- Wang D, Hu B, Hu C et al. (2020) Clinical characteristics of 138 hospitalized patients with 2019 novel coronavirus–infected pneumonia in Wuhan, China. *JAMA.* <https://doi.org/10.1001/jama.2020.1585> ,
- Kenneth L. Zheng et al. (2020) Extra-pulmonary complication of COVID-19: A multisystem disease? *J. Med. Virol.* 2020;1-13:DOI : 10.1002/jmv.26294
- Hansell DM, Bankier AA, MacMahon H, McLoud TC, Muller NL, Remy J (2008) Fleischner society: glossary of thoracic imaging terms. *Radiology.* 246(3):697–722. <https://doi.org/10.1148/radiol.2462070712>
- General Office of National Health Committee. Notice on the issuance of a program for diagnosing and treating novel coronavirus (2019-nCoV) infected pneumonia (trial revised fifth edition). <http://www.nhc.gov.cn/zyygj/s7653p/202003/46c9294a7dfe4cef80dc7f5912eb1989.shtml>. Accessed 3 Mar 2020
- Chinese Society of Radiology (2020) Imaging diagnosis of 2019-nCoV pneumonia: expert recommendation of Chinese Society of Radiology, the first edition. *Chin J Radiol* 54(00):E001–E001. <https://doi.org/10.3760/cma.j.issn.1005-1201.2020.0001>
- Kim EA, Lee KS, Primack SL et al. (2002) Viral pneumonias in adults: radiologic and pathologic findings. *Radiographics* 22 Spec No:S137–S149. https://doi.org/10.1148/radiographics.22.suppl_1.g02oc15s137
- Ooi GC, Khong PL, Müller NL et al (2004) Severe acute respiratory syndrome: temporal lung changes at thin-section CT in 30 patients. *Radiology* 230(3):836–844 75
- The Novel Coronavirus Pneumonia Emergency Response Epidemiology Team The epidemiological characteristics of an outbreak of 2019 novel coronavirus disease (COVID-19) China. accessed on 29 June 2020; *China CDC Wkly.* 2020 41:145. Available online: https://www.cdc.gov/mmwr/Novel_Coronavirus_Reports.html.