



IJCRR

Section: Healthcare  
 Sci. Journal Impact  
 Factor: 6.1 (2018)  
 ICI: 90.90 (2018)

# Lumbosacral Transitional Vertebrae - Occurrence and Significance

Chowki Parvez Abutaher<sup>1</sup>, Patil Rashmi Avinash<sup>2</sup>

<sup>1</sup>Senior Resident, Department of Anatomy, Seth G S Medical College and KEM Hospital, Parel, Mumbai – 400012; <sup>2</sup>Professor (Additional), Department of Anatomy, Seth G S Medical College and KEM Hospital, Parel, Mumbai – 400012.

## ABSTRACT

### Aims:

- To study the occurrence and type of sacralisation of fifth lumbar vertebra
- To correlate embryological basis of the various types of anomalies in the Lumbosacral vertebrae

**Methodology:** 98 adult human sacra were examined in the department of Anatomy of Seth GSMC, Mumbai. Damaged, mutilated and deformed sacra were excluded from the study. The data were collected by naked eye examination, compiled and statistically analysed and compared with other similar studies.

**Results:** The sacralisation of the fifth lumbar vertebra and lumbarisation of first sacral vertebra was respectively seen in 18 out of the 98 sacra studied. This is in close relation with the observations from other studies on Indian population.

**Conclusions:** Genetic factors play an important role in the embryogenesis of lumbosacral Transitional Vertebrae (LSTV). It is important for the clinicians and surgeons to have knowledge of the existence and incidence of LSTVs while performing various clinical and surgical procedures

**Key Words:** Lumbosacral Transitional Vertebrae (LSTV), Lumbar vertebra, Sacrum, Sacralisation, Lumbarisation, Variation

## INTRODUCTION

The Sacrum is a wedge or triangular shaped bone present between the two hip bones. Anatomically, it is formed by the fusion of five vertebrae. Sacrum along with the two hip bones articulates to form the bony pelvis. The base or the upper end of this triangular bone articulates with the fifth lumbar vertebra and the apex or the lower end articulates with the coccyx. It has four pairs of ventral and dorsal sacral foramina that communicate with the sacral canal.<sup>1</sup> Like any other region in the human body, congenital anomalies are very common in this region with an incidence ranging from 3.6% to 18%.<sup>2</sup> These variations are collectively referred to as Lumbosacral Transitional Vertebrae (LSTV).

LSTV include sacralisation and lumbarisation. Sacralisation refers to fusion of the lowest (fifth) lumbar vertebral body to the sacrum and lumbarisation refers to the fusion of the uppermost (first) sacral segment to the lumbar vertebra. In LSTV, the vertebral bodies demonstrate varying morphol-

ogy, ranging from broadened transverse process to complete fusion.<sup>3</sup> Clinically, patients with these variations present with low back pain and lower limb pain. Low back pain associated with an LSTV may arise from the level above the transition or from the anomalous articulation. The association of pain with this congenital anomaly was described by Bertolotti in 1917.<sup>4</sup> It is an important clinical entity as the presence of a LSTV may misguide the diagnosis and treatment. It is thus essential for the clinicians and surgeons to identify the LSTV to avoid an intervention or surgery at an incorrect level.<sup>3</sup>

## MATERIALS AND METHODS

An observational study was carried out on 98 adult human dry sacra in the Department of Anatomy of Seth GSMC, Mumbai. Damaged, mutilated and deformed sacra were excluded from the study. The data was collected by naked eye examination. It was compiled, statistically analyzed and

### Corresponding Author:

Dr. Chowki Parvez Abutaher, Department of Anatomy, 2nd Floor College building, Seth G S Medical College and KEM Hospital, Acharya Donde Marg, Parel, Mumbai - 400012; Email: [parvezchowki@gmail.com](mailto:parvezchowki@gmail.com)

ISSN: 2231-2196 (Print)

ISSN: 0975-5241 (Online)

Received: 14.10.2019

Revised: 04.11.2019

Accepted: 16.11.2019

compared with other similar studies. Lumbarisation and sacralisation were identified based on the examination of the bodies, transverse process and the number of ventral and dorsal sacral foramina. The number of sacra with lumbarisation and the number of sacralisation of lumbar vertebra was noted. (Fig. 1) Depending on degree of fusion of lumbar and sacral vertebrae, sacralisation of the fifth lumbar vertebra was classified as follows:<sup>5</sup>

- 1 Complete fusion: The fifth lumbar vertebra is completely fused with the sacrum. (Fig. 2)
2. Incomplete fusion: The fifth lumbar vertebra is incompletely fused with the sacrum. Incomplete fusion is of following types:
  - a. Bilateral sacralisation: (Fig. 3)
  - b. Unilateral sacralisation: (Fig. 4)

### Study design:

This is a randomized cross sectional study by observations. Descriptive statistics is done by measuring measures of proportions.

### Observations and results:

Of the 98 sacra studied, sacralisation of the fifth lumbar vertebra was seen in eighteen (18) and lumbarisation was seen in eighteen (18) sacra. The sacral hiatus and cornua appeared to be normal in contour in all the sacra studied except for the one sacrum where lumbarisation was seen. (Fig.1)

Out of eighteen (18) sacralised bones, 10 bones showed complete fusion between fifth lumbar vertebra and first sacral vertebra, remaining 08 bones showed incomplete fusion between fifth lumbar vertebra and first sacral vertebra. (Table 1).

Out of 08 incomplete fused bones 04 bones showed bilateral fusion between fifth lumbar vertebra and first sacral vertebra and 04 bones showed unilateral fusion between fifth lumbar vertebra and first sacral vertebra. This unilateral fusion was present in two (02) bones on right side and in two (02) bones on left side. (Table 2)

## DISCUSSION & CLINICAL SIGNIFICANCE

Sacralisation and lumbarisation are the two major components of LSTV. These variations are affected by gender, developmental factors and race. It has been proved that this anomaly is seen to affect males more than females.<sup>6</sup> In the present study we could not study the gender predisposition because of the lack of the available data. It is also proved that sacralisation is more common in occurrence than lumbarisation (2:1).<sup>6</sup> In our study, we found the incidence of sacralisation and lumbarisation was equal as out of the 98 sacra studied 18 were sacralised and 18 were lumbarised. This could be probably because the data studied was insufficient to quote

the incidence rate. But still, our incidence rate of 18% is closer to the incidence reported by Mitchell<sup>7</sup> in Australian aborigines as 18% and by Bustami F<sup>8</sup> in Indians as 16%. Incidence of sacralisation of fifth lumbar vertebra in our study was much higher than incidence reported by Moore & Illinois<sup>9</sup> in Americans as 3.6% and by Brailsford<sup>10</sup> in Natives of Britain as 8 %. (Table 3)

According to Catellvi et al. classification, four types of LSTVs can be identified radiologically. Type I includes unilateral (Ia) or bilateral (Ib) dysplastic transverse process measuring atleast 19 mm in its craniocaudal width. Type II includes incomplete unilateral (IIa) or bilateral (IIB) lumbarisation / sacralisation with an enlarged transverse process that has a diarthrodial joint between itself and the sacrum. Type III indicates unilateral (IIIa) or bilateral (IIIb) lumbarisation / sacralisation with complete osseous fusion of the transverse process to sacrum. Type IV involves unilateral type II transition with a type III on the contralateral side.<sup>10</sup> Majority of the studies refer Catellvi's classification, but since our study was on dried bones we preferred classification given in Cunninghams manual of Practical Anatomy.<sup>5</sup> According to it in our study, we found that out of the 18 sacralised vertebrae, 10 bones showed complete fusion between fifth lumbar vertebra and first sacral vertebra, remaining 08 bones showed incomplete fusion between fifth lumbar vertebra and first sacral vertebra. Out of 08 incomplete fused bones 04 bones showed bilateral fusion between fifth lumbar vertebra and first sacral vertebra and 04 bones showed unilateral fusion between fifth lumbar vertebra and first sacral vertebra. This unilateral fusion was present in two (02) bones on right side and in two (02) bones on left side.

Embryologically, each vertebra is developed from caudal half of onesclerotome and from the cranial half of succeeding sclerotome. Genetically, Notch and the Wnt (Portmanteau of Int and Wg and stands for Wntless-related integration site) signaling pathways are involved in patterning of vertebral column. Simultaneously wavefront of FGF8 expression that moves from the cranial to caudal direction is responsible for patterning of vertebral column. FGF8 expression is lowest in the most cranial, and highest in the most caudal, presomitic mesoderm.<sup>11, 12</sup> Changes in above mentioned gene groups may lead to border shifts which finally would lead to various deformities of vertebral column including LSTV. Sacralisation of fifth lumbar vertebra is due to cranial shift and the lumbarisation of the first sacral vertebra is due to the caudal shift.<sup>6</sup>

## CONCLUSIONS

Lumbosacral Transitional Vertebrae (LSTV) is a condition comprising of either sacralisation or lumbarisation. Genetic factors play an important role in the embryogenesis of this

clinical entity. It is important for the clinicians and surgeons to have knowledge of the existence and incidence of LSTVs while performing various clinical and surgical procedures. Knowledge of sacralisation of fifth lumbar vertebra is important in various therapeutic and diagnostic procedures. Counting of vertebrae from lower end, while doing lumbar puncture or giving spinal anesthesia and epidural anesthesia, may be incorrect in cases of sacralisation of fifth lumbar vertebra. In this condition there is reduced space between L5 and S1 because of which there may be compression of L5 nerve root causing low back pain and sciatic pain.

**ACKNOWLEDGMENT**

Authors acknowledge Dr. Lakshmi Rajgopal, Ex-Professor (Additional), Department of Anatomy, Seth GSMC, Mumbai. Dr. Pritha S Bhuiyan, Professor and Head, Dept. of Anatomy, Seth G.SMC, Mumbai. Dean, Seth GSMC & KEMH, Mumbai. Authors also acknowledge the immense help received from the scholars whose articles are cited and included in references of this manuscript. The authors are also grateful to authors / editors / publishers of all those articles, journals and books from where the literature for this article has been reviewed and discussed.

**Source of funding:** Not applicable

**Conflict of interest:** NIL

**Table 1: Classification of Sacralisation of fifth lumbar vertebra (Total 98 sacra)**

Complete sacralisation	10
Incomplete sacralisation	8
Total	18

**Table 2: Classification of Sacralisation of fifth lumbar vertebra (Total 98 sacra)**

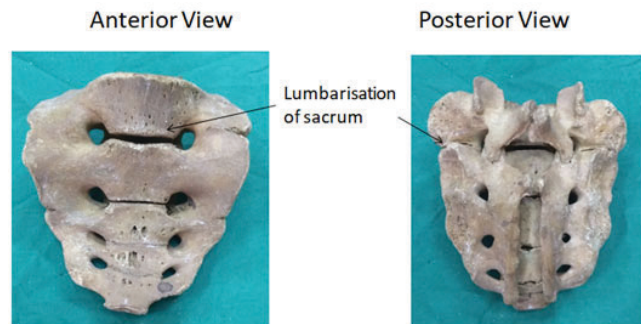
Unilateral sacralisation		Bilateral	Total
Right Side	Left Side	sacralisation	
2	2	14	18

**Table 3: Incidence of sacralisation of fifth lumbar vertebra by various authors**

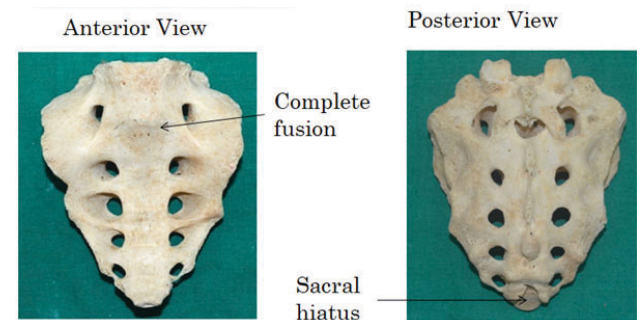
Race	Occurrence	Author
Australian aboriginals	18%	Mitchell (1936)4
Indians	16%	Bustami (1989)5
Americans	3.60%	Moore & Illinois (1925)6
Natives of Britian	8.10%	Brailsford (1928)7
Current study	18.33%	

**REFERENCES**

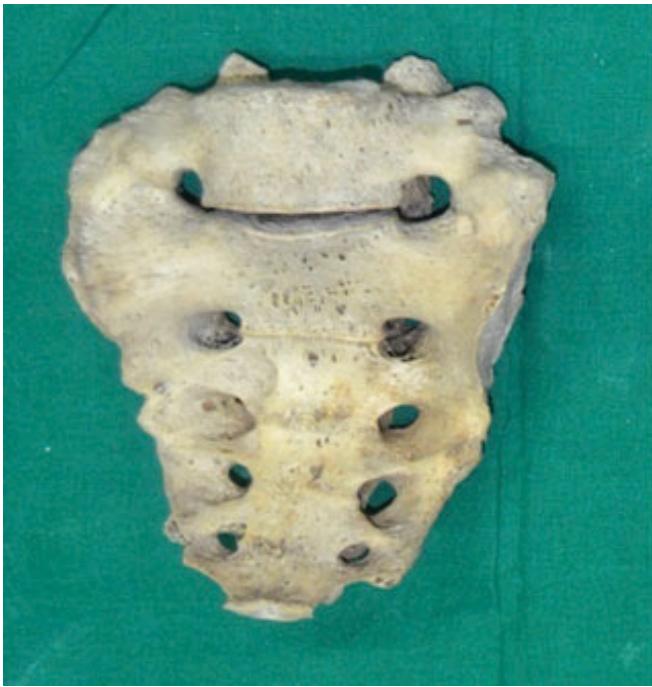1. Adibatti M and Asha K. Lumbarisation of the First Sacral Vertebra a Rare Form of Lumbosacral Transitional Vertebra. *Int. J. Morphol.* 2015, 33(1): 48-50.
2. Nikumbh R.D, Wanjari A.N, Nikumbh D.B. Morphological Study of Sacralisation of Fifth Lumbar Vertebra and Its Clinical Relevance. *Indian Journal of Anatomy.* 2017; 6(2):119-122.
3. Konin G.P and Walz D.M. Lumbosacral Transitional Vertebrae: Classification, Imaging Findings, and Clinical Relevance. *American Journal of Neuroradiology.* 2010; 31(10):1778-1786.
4. Alonzo F, Cobar A, Cahueque M, Prieto JA. Bertolotti's Syndrome: an underdiagnosed cause for lower back pain. *Journal of Surgical Case Reports.* 2018; 10: 1-4.
5. Rachel K. Cunningham's manual of practical anatomy, 16th edition vol. 2, oxford university press, UK; 2017:103.
6. Deepa TK, John MK. A Study of Lumbarisation of First Sacral Vertebra Among the South Indians. *International Journal of Medical Research and Health Sciences.* 2014; 3(1): 1-4.
7. Mitchell GA. The significance of lumbosacral transitional vertebrae. *British Journal of Surgery.* 1936 Jul;24 (93):147-58.
8. Bustami F. The anatomical features and functional significance of lumbar transitional vertebra. *Jordan Med J.* 1989;23:49-59.
9. Moore BH. Sacralisation of the fifth lumbar vertebra. *JBJS.* 1925 Apr 1;7 (2):271-278.
10. Ravikanth R. Majumdar P. Bertolotti's syndrome in low-back-ache population: Classification and imaging findings. *Tzu Chi Medical Journal.* 2019; 31(2):90-95.
11. Brailsford JF. Deformities of the lumbosacral region of the spine. *British Journal of Surgery.* 1929 Apr;16(64):562-627.
12. Moore KL, Persaud TV, Torchia MG. Before we are born: essentials of embryology and birth defects. Elsevier Health Sciences; 2016; 348-356.



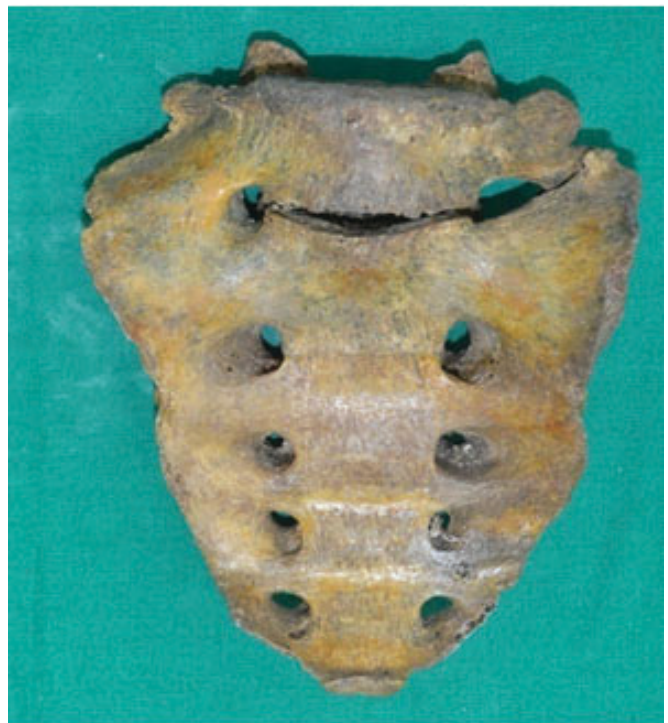**Figure 1:** Lumbarisation of sacrum.



**Figure 2:** Complete fusion between the fifth lumbar vertebra and the sacrum.



**Figure 3:** Incomplete fusion (Bilateral sacralisation).



**Figure 4:** Incomplete fusion (unilateral sacralisation).