



IJCRR

Section: Healthcare  
 Sci. Journal  
 Impact Factor  
 4.016

# UNUSUAL CAUSE OF BLEEDING PER RECTUM IN CHILDREN – CASE REPORT

**Ahmed A. Al-Jarie, Abdullah Hilal, Mohammed R. AL-HAYLI<sup>1</sup>,  
 Zainah A. Sabr, Safa M. AL-Haider, Maha T. almofareh<sup>2</sup>, Nihal I. Mirza<sup>3</sup>**

<sup>1</sup>Pediatric Department, Abha Maternity And Children Hospital, Abha, Saudi Arabia; <sup>2</sup>Department of Child Health, College of Medicine, King Khalid University, Abha, Saudi Arabia; <sup>3</sup>Department of Histopathology, Aseer Central Hospital, Abha, Saudi Arabia.

## ABSTRACT

**Background:** Basidiobolomycosis is a rare fungal infection caused by *Basidiobolus ranarum*. The Zygomycetes includes two fungal orders: Mucorales and Entomophthorales, with completely different pathogenic potentials. *Basidiobolus ranarum* was first described in 1886 in frogs. We present a case of bleeding per rectum in a 3-year-old male patient, resident of Southwestern of Saudi Arabia. The diagnosis was confirmed by characteristic histopathological findings. The aim of presenting the case is to increase awareness among health care professionals in areas of endemicity, so appropriate specimen processing may lead to enhanced case detection and reporting.

**Conclusion:** Antifungal therapy is adequate to cure Gastrointestinal Basidiobolomycosis infection if the fungal mass is unresectable.

**Key Words:** Bleeding per rectum, Gastrointestinal Basidiobolomycosis, Itraconazol

## INTRODUCTION

Basidiobolomycosis is a rare fungal infection caused by *Basidiobolus ranarum*[1] *Basidiobolus ranarum* (*B. haptosporus*, *B. meristoporus*) belongs to the order Entomophthorales in the family of Zygomycota[2,3]. The Zygomycetes includes two fungal orders: Mucorales and Entomophthorales, with completely different pathogenic potentials [4,5,6]. Mucorales involve only the immunocompromised patient, while Entomophthorales, which include *Basidiobolus* genera, causes infection in immune competent individuals, mostly chronic infection of the subcutaneous tissue[4,5,6]. This fungus is an environmental saprophyte found in soil and decaying vegetable materials[7]. This fungus is endemic in some parts of the world such as India[8,9,10]. It is commonly found in soil and decaying vegetable materials and occasionally found as a commensal in the gastrointestinal tracts of amphibians, reptiles, fish, dogs, frogs, and bats[11,12,13]. Fatal cases have been reported in toads [14,15].

## CASE REPORT

A previously healthy 3 year-old male child from Aseer Region (Mohyil in Tohama area) presented to medical attention with history of bleeding per rectum for three months. It was fresh, intermittent bleeding, and small amount. The bleeding was associated with supra pubic abdominal pain, intermittent fever, weight loss (about 4 kg) and diarrhea alternate with constipation in last two months prior to admission. No history of bleeding from other orifices and no jaundice. The patient's past history was unremarkable.

On examination he was pale not jaundiced with normal vital signs. By rectal examination he found to have anterior wall mass rounded smooth 3by 4 cm with fresh blood and no anal fissure or external mass. Other systemic examination was unremarkable. Initial laboratory workup showed WBC  $16.8 \times 10^3/\text{mm}$ , eosinophils 6%, Absolute eosinophilic count 1.0008cell per microliter. Hemoglobin 6.8g/dL, Platelets  $599 \times 10^3/\text{mm}$  and Erythrocyte sedimentation rate 33 mm/hour with normal liver function tests. Abdominal CT-scan

### Corresponding Author:

Ahmed Aljarie, Department of pediatrics, Abha Maternity and Children Hospital, MOH Abha, Kingdom of Saudi Arabia  
 E-mail: aajarie@hotmail.com

Received: 19.11.2015

Revised: 24.12.2015

Accepted: 02.02.2016

showed ill identified solid hypo dense non enhancing lesion measuring 3.5cm by 1.9cm involving the left anterior lateral aspect of the rectum(Figure 1 ).

Patient was admitted as case of bleeding per rectum with rectal mass for investigation. Evacuation of pus collection was done and biopsy was taken .Infectious disease team were consulted. The patient was started on vancomycin , tazocin and liposomal amphotericin B . The gram stain and culture were negative for bacteria and fungus . Acid fast bacilli and culture were negative .The histopathology showed degenerate material and fibrin infiltrated by eosinophils with microabscess formation .Fungal hyphae surrounded by an eosinophilic sheath are seen intermingled within the inflammation ,which was characteristic for Basidiobolomycosis (Figure-2) . Antifungal was changed to itraconazol. No more bleeding or constipation and the mass size regressed with time. follow up CBC showed, WBC = 11.000/mm<sup>3</sup> Hemoglobin = 10.5 gm/dl Platelet =353,000/ mm and normal abdominal ultra sound .

The patient was treated by PO itraconazol for 1 years. He did well tolerated his medication during the course and showed remarkable improvement. His weight at end of therapy was increase by 3 kg.

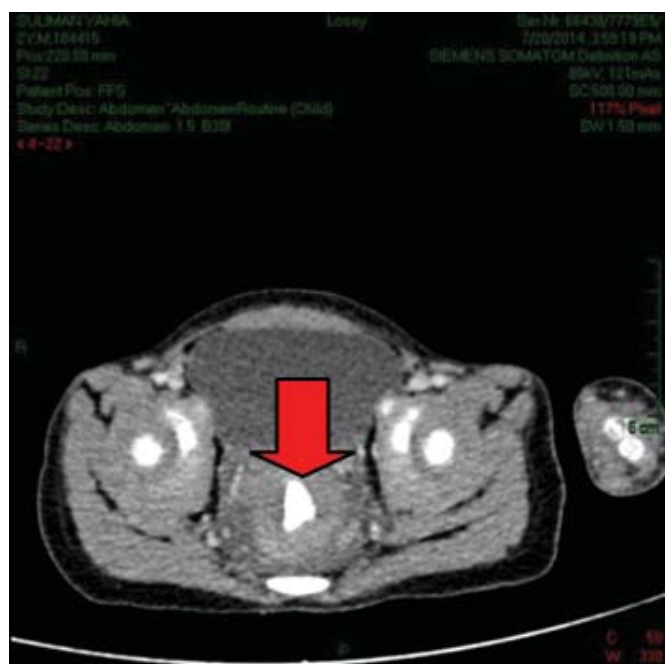


Figure 1: Abdominal CT.

Figure 1. Contrast-enhanced CT scan of abdomen showed ill identified solid hypo dense non enhancing lesion measuring 3.5cm by 1.9cm involving the left anterior lateral aspect of the rectum.

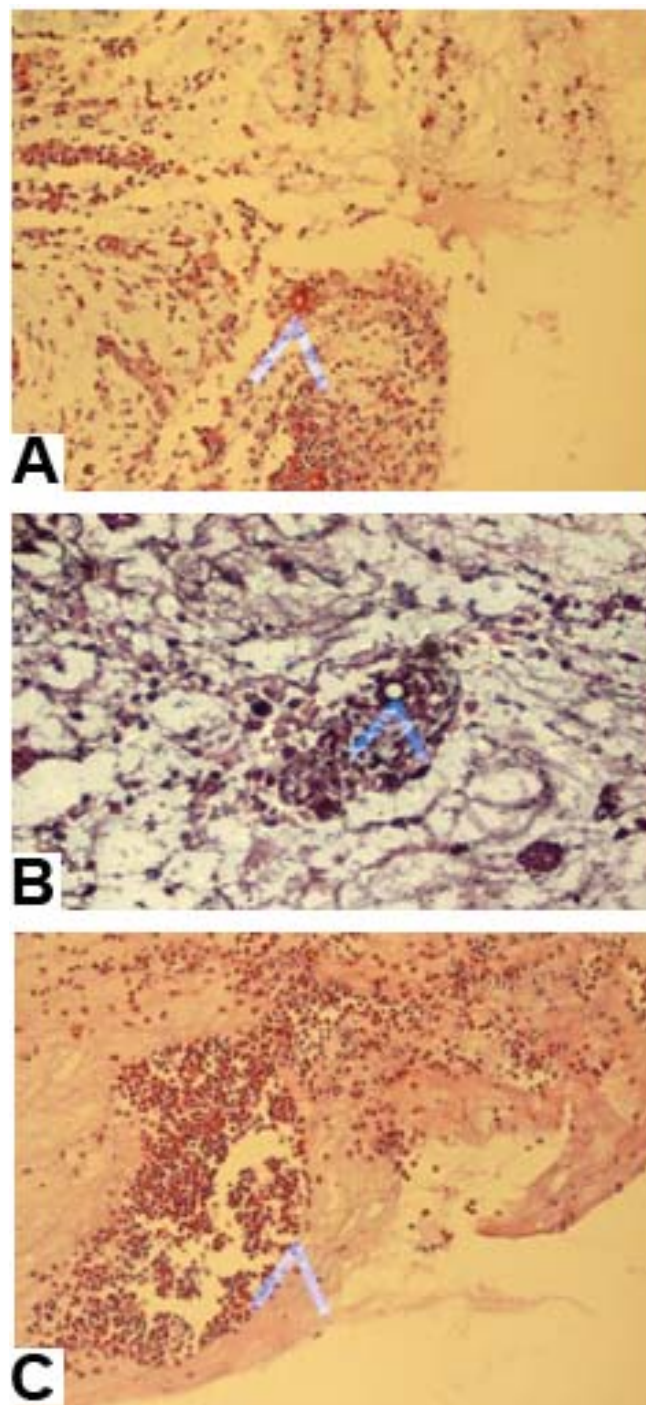


Figure 2

(A): Fungal hyphae of basidiobolomycosis ( arrow) surrounded by eosinophilic sheath ( H&E stain, x 20 magnification).

(B): Fungal hyphae of basidiobolomycosis highlighted by Grocott methamine- silver stain (arrow), x20 magnification.

(C): Eosinophilic microabscess (arrow) within fibrin and degenerate material, (H&E stain, x10 magnification).

## DISCUSSION

Since the first report of GIB in 1964 until the present, there have been 71 cases of GIB, in the English literature. Cases have been reported from Saudi Arabia with 23 cases, Iran with 17 cases, USA with 23 cases, Kuwait with 2 cases, The Netherlands with one case, and Iraq with 6 cases. The patients age ranged from 1.5 to 80 years old. This disease was significantly more common in males; from 71 reported cases, only six patients were female. Nearly all patients had abdominal pain and fever as their initial symptoms; however, some cases additionally had constipation (4 cases), diarrhea (1 case), and gastrointestinal bleeding (1 case). Only one patient presented with mucoid stool. Furthermore, one case presented with perforated appendicitis because of fungal invasion in the appendiceal wall. Radiologic examination by ultrasonography and CT scan were reported in 20 cases. Wall thickening in mass seen 8 and intestinal, gastric or abdominal masses in other 12 cases. There were 3 cases with preliminary diagnosis of inflammatory bowel disease such as Crohn's disease with and without fistula. In 12 reported cases, there were concomitant liver and intestinal masses. The method of diagnosis was pathology and culture. In 32 cases, culture was performed, however only 50% turned out to be positive. Pathologic diagnosis of the cases was characteristic and showed the same picture in all of them, i.e. the presence of Splendore-Hoeppli bodies and many eosinophils as well as intensely radiating eosinophilic granular material surrounding the fungal elements. This histological finding is very characteristic of this fungus and other invasive fungi with gastrointestinal involvement. Mucormycosis causes extensive necrosis and vascular invasion and even their granulomas are morphologically different with no eosinophils. Immunologic diagnosis of *B. ranarum* with methods such as immunodiffusion has been reported, which seems to be specific and has no cross reactivity with other fungi of Entomophthorales; however, its sensitivity is controversial. This immunodiagnostic test can also be helpful for follow up of patients. Molecular diagnosis has also been performed in some reports with optimum results by DNA extracted from formalin fixed paraffin embedded tissue, however, due to the rarity of the disease many centers do not have the set up for this method. Another important concern with this fungal infection is prompt treatment by combined surgery and medical therapy to eradicate disease and prevent early recurrence. Delayed treatment can cause disseminated disease, which has life threatening outcome. Then only and causes postmortem diagnosis can be done on autopsy studies. Additionally, delayed treatment can cause complications such as bowel perforation, obstructive uropathy, esophageal varices, and duodenobiliary fistula [16].

## CONCLUSION

Bleeding per rectum secondary to basidiobolomycosis is extremely unusual and so far no reported cases in pediat-

rics. The aim of presenting the case is to increase awareness among health care professionals in areas of endemicity and appropriate specimen processing may lead to enhance case detection and reporting. The best outcome of this unusual fungal infection is achieved by combination of medical and surgical treatment. In our case the mass was unreachable and patient was cured by medical therapy only.

## ACKNOWLEDGMENT

Authors acknowledge the immense help received from the scholars whose articles are cited and included in references of this manuscript. The authors are also grateful to authors / editors / publishers of all those articles, journals and books from where the literature for this article has been reviewed and discussed.

## REFERENCES

1. Al-Shanafey S, AlRobean F, Bin Hussain Surgical management of gastrointestinal Basidiobolomycosis in pediatric patients. *J Pediatr Surg.* 2012;47:949-51. PubMed PMID:22595579.
2. Anaparthi UR, Deepika G. A case of subcutaneous zygomycosis. *Indian Dermatol Online J.* 2014;5:51-4. doi: 10.4103/2229-5178.126033. PubMed PMID: 24616857; PubMed Central PMCID: PMC3937489.
3. Kumar Verma R, Shivaprakash MR, Shanker A, Panda NK. Subcutaneous zygomycosis of the cervicofacial region: Due to Basidiobolus ranarum. *Med Mycol Case Rep.* 2012;1:59-62. doi: 10.1016/j.mmcr.2012.07.004. PubMed PMID: 24371740; PubMed Central PMCID: PMC3854634.
4. Mohta A, Neogi S, Das S. Gastrointestinal mucormycosis in an infant. *Indian J Pathol Microbiol.* 2011;54:664-5. doi: 10.4103/0377-4929.85149. PubMed PMID: 21934265.
5. Chakrabarti A, Chatterjee SS, Das A, Panda N, Shivaprakash MR, Kaur A, et al. Invasive zygomycosis in India: experience in a tertiary care hospital. *Postgrad Med J.* 2009;85:573- 81. doi: 10.1136/pgmj.2008.076463. PubMed PMID: 19892892.
6. Mantadakis E, Samonis G. Clinical presentation of zygomycosis. *Clin Microbiol Infect.* 2009;Suppl 5:15-20. doi: 10.1111/j.1469-0691.2009.02974.x. PubMed PMID: 19754751.
7. Al-Shanafey S, AlRobean F, Bin Hussain I. Surgical management of gastrointestinal basidiobolomycosis in pediatric patients. *JPediatr Surg.* 2012;47:949-51. PubMed PMID:22595579.
8. Jayanth ST, Gaikwad P, Promila M, Muthusami JC. The Sinus That Breeds Fungus: Subcutaneous Zygomycosis Caused by Basidiobolus ranarum at the Injection Site. *Case Rep Infect Dis.* 2013;2013:534192. doi: 10.1155/2013/534192. PubMed PMID:24349806; PubMed Central PMCID: PMC3852275.
9. Sujatha S, Sheeladevi C, Khyriem AB, Parija SC, Thappa DM. Subcutaneous zygomycosis caused by Basidiobolus ranarum - a case report. *Indian J Med Microbiol.* 2003;21:205-6. PubMed PMID: 17643022.

10. Maiti PK, Bose R, Bandyopadhyay S, Bhattacharya S, Dey JB, Ray Entomophthoromycosis in South Bengal (Eastern India): a 9 years study. *Indian J Pathol Microbiol.* 2004;47:295-7. PubMed PMID: 16295506.
11. Saadah OI, Farouq MF, Daajani NA, Kamal JS, Ghanem AT. Gastrointestinal basidiobolomycosis in a child; an unusual fungal infection mimicking fistulising Crohn's disease. *J Crohns Colitis.* 2012;6:368-72. PubMed PMID: 22405176.
12. Rabie ME, El Hakeem I, Al-Sharim M, Al Skini MS, Jamil S. Basidiobolomycosis of the colon masquerading as stenotic colon cancer. *Case Rep Surg.* 2011;2011:685460. doi: 10.1155/2011/685460. PubMed PMID: 22606589; PubMed Central PMCID: PMC3350237.
13. Paré JA. Fungal diseases of amphibians: an overview. *Vet Clin North Am Exot Anim Pract.* 2003;6:315-26. PubMed PMID: 12827724.
14. Taylor SK, Williams ES, Mills KW. Mortality of captive Canadian toads from *Basidiobolus ranarum* mycotic dermatitis. *J Wildl Dis.* 1999;35:64-9. doi: 10.7589/0090-3558-35.1.64. PubMed PMID: 10073347.
15. Taylor SK, Williams ES, Mills KW. Experimental exposure of Canadian toads to *Basidiobolus ranarum*. *J Wildl Dis.* 1999;35:58-63. doi:10.7589/0090-3558-35.1.58. PubMed PMID:10073346.
16. Bitá Geramizadeh, Mina Heidari, Golsa Shekarkhar, Gastrointestinal Basidiobolomycosis, a Rare and Underdiagnosed Fungal Infection in Immunocompetent Hosts, A Review Article, *Iran J Med Sci* March 2015.