



IJCRR
Section: Healthcare
Sci. Journal Impact
Factor: 5.385 (2017)
ICV: 71.54 (2015)

Core Biopsy Diagnosis of Infantile Fibrosarcoma: Case report

Sachin B. Ingle¹, Chitra R. Hinge (Ingle)²

¹Department of Pathology, MIMSR Medical College, Latur, Maharashtra-4132512, India; ²Department of MIMSR, Medical College, Latur, Maharashtra-4132512, India.

ABSTRACT

Clinical as well as radiologic diagnosis of infantile fibrosarcoma (IFS) is often a challenging problem due to Similarities with tumors of vascular origin. Consequently, in the majority of cases, histological and immunohistochemical studies are considered gold standards for the final diagnosis. Herein we are reporting an interesting case of infantile fibrosarcoma in a female child with unusual presentation of swelling at first web space on palmar aspect. diagnosis of which was done on histopathology and confirmed on immunohistochemistry.

Key Words: Infantile fibrosarcoma, Upper extremity tumors, Vascular tumors, Core biopsy and Immunohistochemistry

INTRODUCTION

IFS are a mesenchymal malignant hypervascular tumor and the most common soft tissue sarcoma in children younger than 1 year of age. The incidence of IFS was Found to be more common in the male gender. It is less commonly presenting beyond the age of 2 years. This tumor frequently gets misdiagnosed initially as a hemangioma or an arteriovenous malformation due to its vascularity and presentation. Several literature reports discuss the similarities in differential diagnosis between vascular

Tumors and infantile fibrosarcoma (IFS) [1]. This case report, presented a 2 years old girl with a mass in her hand which was relapsed locally. The tumor location, radiological and histopathological findings proved the diagnosis of fibrosarcoma. In this age, infantile fibrosarcoma is rare and generally misdiagnosed because of histological similarities to benign tumors.

Core tip-Juvenile fibrosarcoma have real diagnostic dilemma on histopathology because of its resemblance with benign vascular neoplasms. So careful evaluation of biopsy and IHC is must to hit the diagnosis.

since 2 months. She was previously operated for the same and diagnosed as infantile capillary hemangioma on histopathology at other centre. The recurrence of swelling occurred. The core needle biopsy of the swelling was planned and performed and the biopsy sample sent to histopathology department. We suspected it as a sarcoma on morphological grounds.. In view of local recurrence and mitotic activity we decided to send the blocks for immunohistochemical evaluation to rule out sarcoma. At higher centre oncopathologist revealed a cellular spindle cell sarcoma showing nuclear atypia, brisk mitotic activity (approximately 15/10 HPF) and a pericytomatous vascular stroma. A sprinkling of lymphocyte is noted within the tumor (**Fig. 1**).

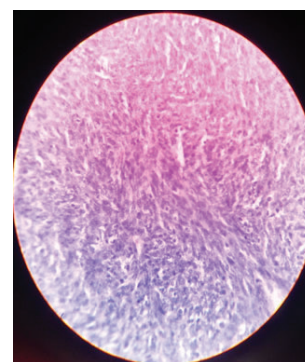


Figure 1: Showing high power view of a cellular spindle cell sarcoma.

CASE REPORT

A 2 year female child came in YCR hospital, Latur with the complaint of swelling over the first web of the right hand

Corresponding Author:

Sachin B. Ingle, Professor, Department of Pathology and Secretary Research & Development, Institutional Review board, MIMSR Medical College, Ambajogai Road, vishwanathpuram, Latur-Maharashtra 413531 India; Tel: +91-2382-227424; Fax: +91-2382-228939; Email: dr.sachiningle@gmail.com

ISSN: 2231-2196 (Print)

ISSN: 0975-5241 (Online)

Received: 01.07.2018

Revised: 28.07.2018

Accepted: 29.08.2018

Then they went for immunohistochemistry. On immunohistochemical evaluation the tumor cells were immunopositive for CD 34 (Fig. 2) and SMA (focal) (Fig. 3) and are immunonegative for desmin and S-100 protein. Finally the case was diagnosed as infantile fibrosarcoma and treated with wide excision with negative margins and on follow up doing well since last one year.

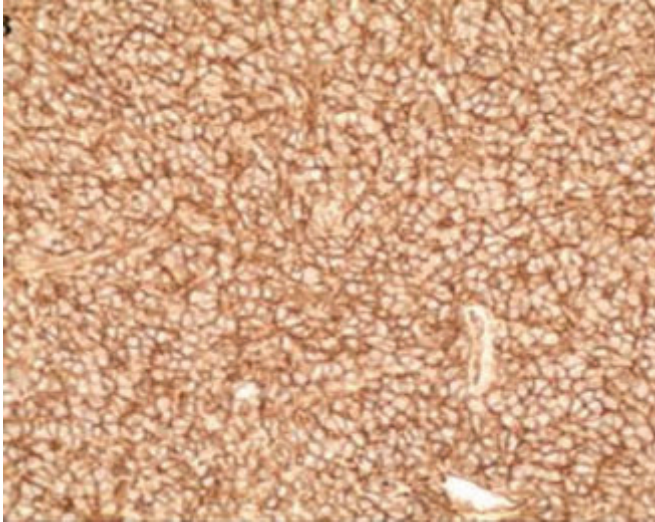


Figure 2: Showing positivity for CD 34.

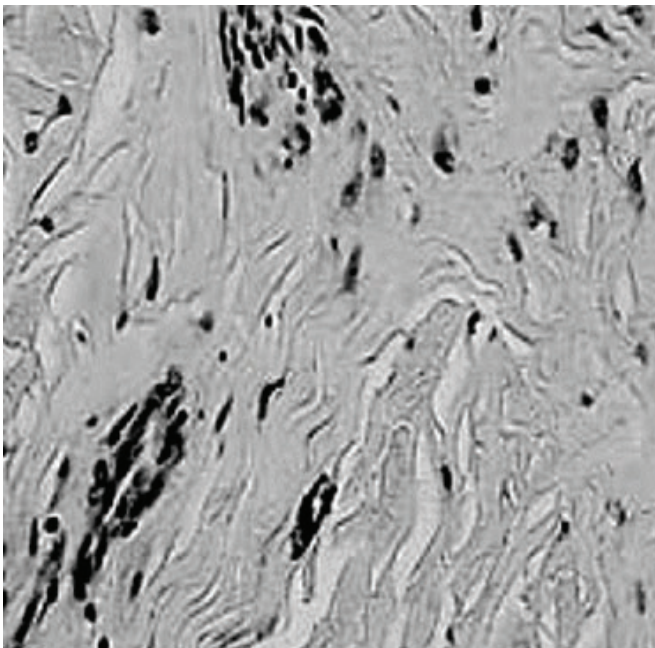


Figure 3: Showing Focal positivity for SMA.

DISCUSSION

IFS is also known and described in the literature in many synonyms such as congenital fibrosarcoma, juvenile

fibrosarcoma, medullary fibromatosis of infancy, aggressive infantile fibromatosis, desmoplastic fibrosarcoma of infancy. It is histologically indistinguishable from the adult fibrosarcoma. The sites most commonly involved are the extremities, followed by the spine, head and neck). IFS incidence is very low and is estimated to be five per million infants. It is a mesenchymal malignant hypervascular tumor and the most common soft tissue sarcoma in children younger than 1 year of age with slight male predominance. Our case was a 2 year female child presented with swelling over the first web space of the right hand.

IFS are typically large tumors that grow very rapidly. These tumors are highly vascularised and may have ulcerations and bleeding, making it clinically difficult to differentiate them from hemangiomas. Our case was also diagnosed as hemangioma at other centre on histopathology. IFS are more commonly seen in boys than girls and typically involve distal extremities (66 %) and trunk (25 %).

However, for unknown reasons, IFS has a much better prognosis, a lower rate of metastasis, and a high 10-year survival rate (89–90 %) as compared to the adult patients whose 5-year survival does not exceed 50 %. Fibrosarcoma is less common in infants than in adults, where it tends to present in a more central distribution ^[1].

While considered a non-aggressive form of sarcoma, complete surgical resection is rarely feasible at diagnosis. Nearly half of the patients require chemotherapy to reduce tumor size before surgery, and/or to prevent recurrence after surgery. The role of radiotherapy is debated and is mostly reserved as salvage therapy or to preserve the organ function ^[3]. Each radiation schedule can be converted to biologically effective doses (BEDs) using the following formula and are compared on the same scale, where n is the number of fractions; d, the dose per fraction; and α/β , the alpha beta ratio for irradiated tissue with the BED for spinal cord being 3 (BED3)9).

$BED = nd (1 + d / \alpha/\beta)$ [2] Surgery has traditionally been considered the treatment

Of choice for IFS. The radicality of first surgery, aimed at achieving histopathologically negative margins, is associated with best prognosis. If a negative histopathological margin is obtained, long term disease free survival can be achieved even without any adjuvant

Therapy as happened in our case. However the role of adjuvant therapy is controversial in such cases. In patients with IFS involving the limbs, however, the issue of loss of function after surgery assumes importance. In such patients, chemotherapy has the potential of decreasing the size of tumor, thereby obviating the need of extensive surgery and making function preserving surgery a possibility. This case

emphasizes the importance of radical excision with negative margins is an important determinant of long term disease free survival in infantile fibrosarcoma.

CONCLUSION

For the better prognosis and early treatment of the tumor, the meticulous diagnosis should be made early. The contribution of pathologist and his suspicion is required for accurate histological diagnosis.

ACKNOWLEDGEMENT

We are grateful to our executive president Prof Dr V D Karad and executive director Shri Rameshappa Karad for the invaluable support for our work and also thankful to scientific officer Mrs Shilpa from IJCRR for the technical guidelines

REFERENCES

1. Hayek SN, Janom HH, Ibrahim A, Moran SL, et al; Infantile fibrosarcoma misdiagnosed as a vascular tumor- American association for Hand Surgery 2013. 20 March 2013.
2. Cheng-Hsiang Lo, M.D., Shin-Nan Cheng, M.D., Kuen-Tze Lin, M.D., Yee-Min Jen, M.D., Ph.D., et al; Successful Treatment of Infantile Fibrosarcoma Spinal Metastasis by Chemotherapy and Stereotactic Hypofractionated Radiotherapy-J Korean Neurosurg Soc 54 : 528-531, 2013.
3. Daniela Alexandru, Denise K. Van Horn, Daniela Annenelie Bota, et al; Secondary fibrosarcoma of the brain stem treated with cyclophosphamide and Imatinib- J Neurooncol (2010) 99:123–128.
4. Amirataollah Hiradfar. Tala Pourlak. Davoud Badebarin, et al; Primary Pulmonary Fibrosarcoma With Bone Metastasis: a Successful Treatment With Post-Operation Adjuvant Chemotherapy- Iran J Cancer Preven. 2015 May; 8(3):e2328.
5. Nirali N. Shah, MD, Mitchell R. Price, MD, David M. Loeb, MD, PhD, et al; Cardiac Metastasis and Hypertrophic Osteoarthropathy in Recurrent Infantile Fibrosarcoma-Pediatr Blood Cancer. 2012 July 15; 59(1): 179–181.