



IJCRR  
Section: Healthcare  
Sci. Journal Impact  
Factor: 5.385 (2017)  
ICV: 71.54 (2015)

# Clinical and Anatomical Study of Retromolar Foramen on Adult Dry Mandible in Uttarakhand Region in India

Shikha Malik<sup>1\*</sup>, Sunita<sup>2</sup>, Alok Choudhary<sup>3</sup>

<sup>1</sup>Demonstrator, Department of Anatomy, Glocal Medical College Super Specialty Hospital and Research Centre, Mirzapur Pole, U.P. - 247121, India; <sup>2</sup>Demonstrator, Department of Anatomy, Glocal Medical College Super Specialty Hospital and Research Centre, Mirzapur Pole, U.P. - 247121, India; <sup>3</sup>Associate Professor, Department of Anatomy, Shri Guru Ram Rai Institute of Medical and Health Sciences, Dehradun, U.K. - 248001, India.

## ABSTRACT

**Aim and Objective:** The aim of the present study is to observe and analyze the morphological variations found in retromolar foramen and to assess the average width of Retromolar foramen.

**Material and Methods:** In this study all available 72 dry, fully ossified adult mandibles from the department of Anatomy, Shri Guru Ram Rai institute of medical and health sciences, Dehradun, Uttarakhand north region of India were included without gender and age distinction. In 72 dry mandibles, the mandible which has retromolar foramen was studied for its diameter along with side preference.

**Result:** The diameter of the Retromolar foramen varies between 0.53 to 1.64 mm and the mean Diameter of foramen was 1.01mm. The mean width of Retromolar foramen in right side was 1.01mm which is same as of Left side (1.01mm).

**Conclusion:** The retromolar foramen and canal act as a common risk factor while performing conventional anesthetic techniques so the knowledge of the variation is relevant and after evaluating the width of the foramen which is not negligible surgeons must be careful about the anatomical structures that enter via Retromolar foramen, which can be injured during surgical approaches..

**Key Words:** Retromolar Triangle, Retromolar foramen, Retromolar canal

## INTRODUCTION

A triangular area posterior to the third molar tooth on the alveolar surface of mandible known as retromolar triangle. Posterior to the lower third molar is a cribrose triangle, the retromolar triangle, and laterally, the retromolar fossa.<sup>1</sup> The boundary of retromolar fossa is formed from the medial side by temporal crest & from the lateral side by the anterior border of ramus.<sup>2</sup> The retromolar foramen (RMF) of the mandible is a variant anatomical structure which is present on the retromolar fossa along with retromolar canal in Retromolar Triangle. It is sharp and narrow, and medially borders the extramolar sulcus (at the buccal edge of the third molar).<sup>3</sup> This foramen runs straightly to the retromolar canal (RMC), which diverges from the mandibular canal and present as a morphologic and morphometrical variability.<sup>4</sup> In the content of the Retromolar canal there is an artery which is a branch of the inferior alveolar artery, and a nerve derived from the

inferior alveolar nerve and went towards the third molar region, the retromolar triangle mucosa, the buccal mucosa, the vestibular gingiva of the premolar region, and the inferior molars.<sup>5</sup> Some researchers<sup>4,6,7</sup> studied about the content of the canal and suggested that they emerges from the mandibular neurovascular bundle before enters into the mandibular canal and some other researchers<sup>5,8,9,10</sup> studied that it arise from neurovascular bundle in mandibular canal and lie in buccal area.

According to the Japanese research studies retromolar canal is an extension through retromolar foramen on retromolar fossa of the body of the mandible through which the neurovascular bundle passed which has nerve and artery. This neurovascular bundle provided supply to the lower third molar, mucosa of retromolar triangle and the buccal gingival of premolar and molar area. The artery anastomosed with the branches of buccal artery and the facial artery after arising from

### Corresponding Author:

Shikha Malik, Demonstrator, Anatomy Department, Glocal Medical College Super Specialty Hospital and Research Centre, Mirzapur Pole, Saharanpur, U.P. - 247121, India. E-mail: shikhamalik99.sm@gmail.com

ISSN: 2231-2196 (Print)

ISSN: 0975-5241 (Online)

Received: 18.07.2018

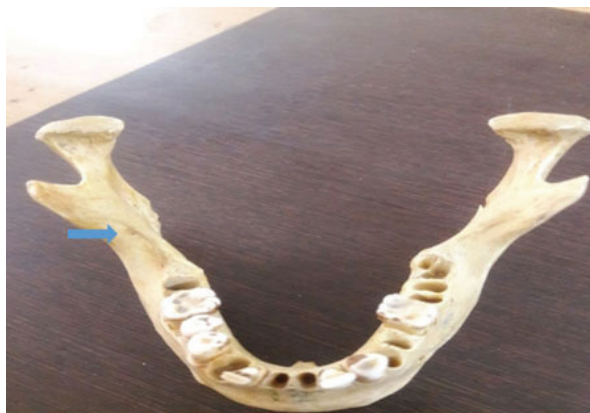Revised: 29.07.2018

Accepted: 14.08.2018

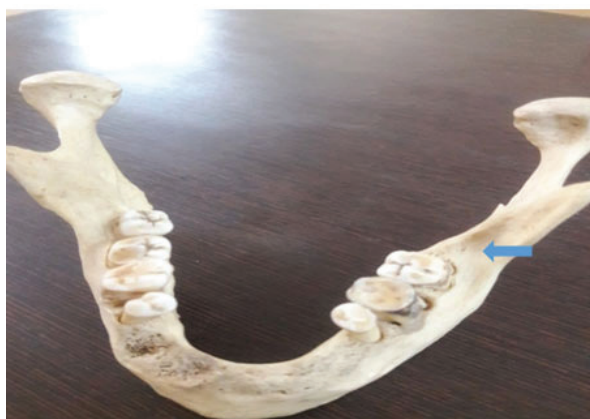the mandibular canal. Anthropological studies conducted that included 2500 number of mandibles of different human groups indicated that the Retromolar foramen can be found in diverse populations more common in native populations of North America than other populations of Africa, Europe, India and Northeast Asia.<sup>11</sup> The information about the morphology of the mandible and its anatomical differences is very important in the preparation of various dental clinical procedures which rests on the presence of the neurovascular bundle, which passes through it.

## MATERIAL AND METHOD

In this study all available 72 dry, fully ossified adult mandibles from the department of Anatomy, Shri Guru Ram Rai institute of medical and health sciences, Dehradun, Uttarakhand north region of India were included without gender and age distinction. In 72 dry mandibles each mandible was observed for morphological variations that is retromolar foramen and the mandible with foramen were evaluate for the diameter of retromolar foramen along with side preference(Fig no.1 & 2).



**Figure 1:** Retromolar Foramen on the Right Side of Mandible in Triangular Fossa.



**Figure 2:** Retromolar Foramen on the Left Side of Mandible in Triangular Fossa.

Mandibles showing signs of pathology or other processes which may have influenced result (osteopetrosis, advanced alveolar bone resorption in the retromolar area) etc. and mandibles with the signs of damage to the retromolar area whether due to the ageing or handling of mandibles were excluded.

## RESULT

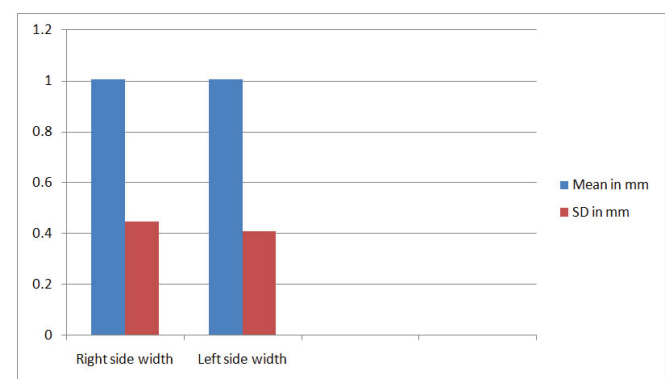
In our findings it shows that the diameter of the Retromolar foramen varies between 0.53 to 1.64 mm and the mean diameter of the Retromolar foramen is 1.0 mm and the mean width of the RMF on right side (1.01mm) is same as that of the left side (1.01mm) showing in Table no.1,2 & Graph no.1.

**Table 1: Measurements of Diameter of Retromolar Foramen**

Total No. of Foramens	Min. Width	Max. Width	Mean Width	SD
30	0.53	1.64	1.01	±0.35

**Table 2: Comparison of Retromolar Foramen width between Right and Left side on mandible**

Right side			Left side		
Number of foramen	Mean width	SD	Number of foramen	Mean width	SD
13	1.01	0.45	17	1.01	0.37
Min - 0.69			Min - 0.53		
Max - 1.48			Max - 1.64		



**Graph 1:** Comparison Between the Right side and left side width of retromolar foramen on mandible.

## DISCUSSION

A triangular area behind the third molar tooth on the alveolar surface of mandible known as retromolar triangle. 72 human

mandibles are examined in the present study for the diameter of the retromolar foramen along with the side preference. The diameter of the Retromolar foramen varies between 0.53 to 1.64 mm and the mean Diameter of foramen is 1.01mm. The mean width of Retromolar foramen in right side is 1.01mm which is same as of Left side (1.01mm). The above findings show that the right Retromolar Foramen is of same width as Left foramen.

In findings it shows that the mean diameter of the Retromolar foramen is 1.01 mm which was in part accordance with the study conducted by Md. A. Khan<sup>12</sup> which showed that the mean diameter of the Retromolar foramen was 1.25 mm. The variation is possible because of the sample size. In our finding it is showed that the width of the Retromolar foramen on right side (1.01mm) is same as that of the left side (1.01mm), which was not in accordance with the study conducted by the Md. A. Ashraf Khan and Senthil Kumar.S<sup>13</sup> both stated that the left Retromolar foramen was larger than right. The differences in these studies may be due to differential origin in Indian population and their sample size.

## CONCLUSION

The diameter of Retromolar foramen through which the nerves and artery passes less than 1mm was not considered as foramen and the diameter of the Retromolar foramen on both right and left side were found same. The constituent of retromolar foramen and canal are the nerves that provides innervation to the pulp of third molar, retromolar area, fibers of the temporalis and buccinator muscle.<sup>14</sup> Presence of retromolar foramen and canal and its contents have great clinical implication and can be damaged in various surgical activities like flap lifting, bone tissue for autologous bone grafts, osteotomy for the surgical removal of third molar, placement of Osseo integrated implants for orthodontic or in sagittal split osteotomy surgeries<sup>15</sup> so retromolar foramen is considered as potential route for further innervation to the lower third molar area causing failure in anesthetic mandibular blocking.

## REFERENCES

1. Suazo GI, Cantín LM, López FB, Valenzuela UV, Valenzuela RR. Morphometric study of the retromolar triangle. *Int J Odontostomat*. 2007. Vol.1 (2):129-32.
2. Susan Standring, "Infratemporal and pterygopalatine fossae and temporomandibular joint" in *Grays Anatomy: The Anatomical Basis of Clinical Practices*, S.Standring, H. Ellis, J.C. Healy, D. Jhonson and A. Williams, Eds., Churchill Livingstone, New York, NY, USA, 40 th ed, 2008. Pp. 532.
3. M. Lipski, I.M. Tomaszewska, W. Lipska, G.J. Lis, K.A. Tomaszewski. The mandible and its foramen: anatomy, anthropology, embryology and resulting clinical implication. *Folia Morphol*.2013.vol.72, no.4, pp.285-292. DOI: 10.5603/FM.2013.0048.
4. K Narayana, U A Nayak, W N Ahmad, J G Bhat, B A Devaiah. The retromolar foramen and canal in south Indian dry mandibles. *European Journal of Anatomy*. 2002; 6 (3): 141-146.
5. Koder H, Hashimoto I. A case of mandibular retromolar canal; elements of nerves and arteries in this canal. *Kailbogaku Zashi*. 1995; 70 (1): 23-30.
6. Kaufman E, Serman NJ, Wang PD: Bilateral mandibular accessory foramina and canals: A case report and review of the literature. *Dentomaxillofac Radiol* 29:170, 2000.
7. Wang PD, Serman NJ, Kaufman E: Continious radiographic visualization of the mandibular nutrient canals. *Dentomaxillofac Radiol* 30:131, 2001
8. Ikeda K, Ho KC, Nowicki BH, et al: Multiplanar MR and anatomic study of the mandibular canal. *Am J Neuroradiol* 17:579, 1996.
9. Ossenberg NS: Temporal crest canal: Case report and statistics on a rare mandibular variant. *Oral Surg Oral Med Oral Pathol* 62:10, 1986.
10. Ossenberg NS. Retromolar foramen of the mandible. *Am J Phys Anthropol*. 1987; 73: 119-28.
11. Silva FM, Cortez AL, Moreira RW, Mazzonetto R. Complications of intraoral donor site for bone grafting prior to implant placement. *Implant Dent*. 2006. vol. 15; 420-26.
12. Md. A.Khan, S.Agarwal, R.S. Mandloi. Prevalence of Retromolar Foramen in Dried Mandible along with Morphometric and Analytical study in North India. *Natl J Med Dent Res*. 2013. Vol. 2(1): 11-14.
13. Senthil Kumar S, Kesavi D. A Study on the incidence of Retromolar Foramen and Canal in Indian Dried Human Mandibles and its Clinical Significance. *International Journal of Anatomical Sciences*. 2010. Vol.1: 14-16.
14. Reyneke J. P, T sakiris P & Becker P. Age as a factor in the complication rate after removal of unerupted/ impacted third molars at the time of mandibular sagittal split osteotomy. *J. Oral Maxillofac. Surg*. 2002; 60(6): 654-659.
15. Boronat Lopez A & Penarrocha Diago M. Failure of locoregional anesthesia in dental practice. Review of the literature. *Med. Oral Patol. Oral Cir. Bucal*. 2006; 11(6): 510-513.