



IJCRR

Vol 05 issue 06

Section: Healthcare

Category: Research

Received on: 09/02/13

Revised on: 27/02/13

Accepted on: 15/03/13

EVALUATION OF FERTILITY EFFICACY OF IONIDIUM SUFFRUTICOSUM EXTRACT ON SENILITY INDUCED STERILITY OF MALE ALBINO RATS

B. Senthil Kumar¹, J. Vijaya Kumar², R. Selvaraj³¹ Department of Anatomy, Vinayaka Mission's Kirupananda Variyar Medical College and Hospital, Saveetha University, Salem, India² Department of Anatomy, Saveetha Medical College, Chennai, India³ Biomedical Research Unit and Lab Animal Centre, Saveetha University, Chennai, India

E-mail of Corresponding Author: skdrchinu88@gmail.com

ABSTRACT

Background: Ageing is associated with the diminished function of various tissues in the body. The gonadal function decreases with the increase in age. Testes undergo atrophy resulting in shrinkage of seminiferous tubules due to reduced testosterone hormone level in elderly male. The process of spermatogenesis decreases in old age when compared to young adults. Today's lifestyle makes an adult sub fertile even in their earlier age of 30-40 years. To overcome this problem many non-hormonal preparations are in need, so an herbal trial was planned initially on animals which will be followed up to humans in future, if the herb proved to be safe.

Objective: To evaluate the fertility efficacy of Ionidium suffruticosum extract on senility induced sterility of male albino rats.

Research Methodology: A total of 16 healthy senile male albino rats weighing 300 to 330 gm were selected. Ionidium suffruticosum extract of 200mg/kg bodyweight were administered orally to the senile experimental albino rats (n=8) and compared to the senile control albino rats (n=8) using various parameters and the drug's efficacy was proved by the restitution of fertility in senile rats.

Results: The administration of the drug showed significant improvement of all the parameters in experimental rats when compared to control rats. The data's were analyzed using student's t test and found to be statistically significant.

Conclusion: The herb was found to be effective on the gonads of senile male albino rats, regaining its fertility to normal, when compared to control rats.

Keywords: Ionidium suffruticosum, senile rats, Sterility, Seminiferous tubule, Siddha Medicine

INTRODUCTION

In our day-to-day life, change in culture and food habits, adulteration, exposure to various radiations, chemical hazards, pollution, smoking, and alcohol, and various diseases like hypertension, diabetes mellitus, obesity, and resultant grave side effects of medication for these conditions, impacts the human species with dangerous and unexpected complications on fertility in life. Even recent studies reveal the fact that, the usage of electronic devices such as mobile phones and its radiations, affect the

gonads to a great extent. ^[1] Ageing is associated with the diminished function of various tissues in the body. This decline in the organism's capacity for optimal functioning may be attributed to changes arising out of involution and wear and tear of the tissues. With age, there are also changes occurring in the cell membrane and chemicals, particularly in the cellular enzymes. The gonadal function declines with age. In the male, there is progressive atrophy of the sperm-producing elements of the testis, resulting in diminished spermatogenesis. ^[2]

There is a remarkable increase in the use of herbs over the past few years and research interests have focused on various herbs. According to Siddha system of medicine (Indian Medicine) many herbs were used for treating male sexual disorders since ancient times. Several non-hormonal herbal preparations have been used to correct such sexual disorders. Apart from these preparations some individual herbs also have the effect of treating such sexual disorders. The present research was undertaken to study the aphrodisiac effect of individual herb *Ionidium suffruticosum* (Ging) on fertility of senile male albino rats.

MATERIALS AND METHODS

a) Animal selection

The study was done on 16 healthy senile male albino rats (*Rattus norvegicus*) of Wister lineage with an average weight of 300 – 330 gm of 16-18 months were housed in the cages and fed with standard pellets and given fresh water ad libitum and acclimatized on a 12 hour light & 12 hour dark schedule.^[3] The study was approved by Saveetha University Animal ethical committee approval reference no- ANAT.005/2012. The rats were divided into 2 groups control (n = 8) and experimental (n = 8) by random allocation method. The cages are labeled with group, weight of the animal and dosage of the drug. About one week was given for the acclimatization of rats. The *Ionidium suffruticosum* (Ging) extract was prepared as per our protocol.^[4] About 200 mg / kg bodyweight was diluted with adequate amount of sterile water and administered orally to the experimental group using oral gavage tube and simultaneously sterile water were given orally to control rats (placebo). The drug was administered as single dose, once a day for 30 days regularly to all the experimental animals. Rest period of about 10 days were given to all the animals after drug administration. The sexual behaviour was observed as per our previous study protocol.^[5]

b) Sample collection

The rats were anaesthetized using Xylazine & ketamine.^[6] A vertical incision was given ventrally and jugular vein was traced out, about 2ml of blood was taken followed by midline thoraco-abdominal incision was given and the heart was perfused with normal saline followed by buffered formalin until blanching and twitching occurs in the animal. Scrotum was incised and the testicles were removed. The epididymis was removed from the testes by fine dissection.^[7]

I) Measuring dimension of testes

The lengths, breadth, height and weight of the testes were measured as per the method used in our previous study.^[8] The volume of the testis were calculated using the Lambert's formula^[9] (Volume = Length x Breadth x Height x 0.71 cu.cm). The testes were fixed by gendre's fluid (Fixative) for 48 hrs. The relative weight of testes gonado-somatic index (GSI) were calculated with the help of following formula (GSI = Weight of testes in grams / Body Weight in grams x 100) where weight of Testes (Absolute weight in gram) and body Weight (weight of rats on the 40th day in gm).^[10, 11] The data's were tabulated.

II) Semen and serum testosterone hormone analysis:

The semen samples were collected from the epididymis and sperm count was done as per standard protocol followed in our previous study.^[8] Smears were also prepared from the semen samples. The slides were stained by Papanicolaou stain.^[12] The morphological characteristic of the sperm cells in all the smears were observed under oil immersion (100 X). The numbers of normal and abnormal sperm cells were tabulated for both control and experimental group, by counting 200 sperm cells per smear and two smears per rat randomly. The data's were analyzed by Chi-Square test. Serum was separated, from the blood sample. Testosterone hormone level was estimated using ELISA analyzer and the readings were noted down.

III) Histomorphometry of testes

The Gendre's fluid fixed testes were processed in different percentage of alcohol, xylene and embedded in paraffin wax. Eight sections (5 µm thick) were taken at different levels in each half of testis using rotary microtome and stained by haematoxylin and eosin.^[12, 13]

The stained slides were mounted and carefully observed for histological changes and morphometric analysis was done. Micrometry was used to measure the diameter of the seminiferous tubules. The stained slides were focused under 10x objective, about 50 tubules diameter was measured using Magnus pro image analysis software and calculated using the formula (Diameter of seminiferous tubules = Maximum length + maximum breadth / 2 µm).^[14, 15, 16] The mean diameter was taken from the 50 seminiferous tubules per section of testes. The final average diameter of the seminiferous tubules of each animal was tabulated. The mean, standard deviation, Standard error mean were calculated and tabulated. Further all the parameters data's were analyzed by student's t test using Graph pad software quick calcs online calculator for scientist.^[17]

RESULTS

Various parameters such as sexual behaviour, body weight of animals, dimension of testes, hormonal analysis, semen analysis, histological analysis of testes, histomorphometry of seminiferous tubules, and diameter of seminiferous tubules were tabulated (Table 1 & 2) and all the parameters were analyzed using student's t test except sperm morphology which was analyzed by Chi-square test. The data's analyzed were found to be statistically significant. The administration of the drug showed significant improvement of all the parameters in experimental rats when compared to control rats and the drug's efficacy was proved by the restitution of fertility in senile rats.

DISCUSSION

The mounting index has shown variation among the control and experimental rats and it proves that there is some effect of Ionidium on the male sexual activity of senile rats. The total sexual behavior of the rats were observed and the sexual activity was more in experimental rat when compared to the control rats resulting in statistically significant (Table 1). The weight of control rats were more or less equals when compared to the experimental rats. There is no much gain of weight in senile rats when compare to young rats from our previous study and the weight gain is statistically not significant.^[8] The results pertaining to the weight and volume of the testes and GSI were analyzed which showed a marked difference between the Control and experimental rats respectively. The testes of control rats showed seminiferous tubules with much shrinkage and loss of their tubular appearance and the lumens appear empty (Fig 1).^[18] Whereas the experimental rats have regained more or less normal seminiferous tubules (Fig 2) and these changes resulted the increase in weight, volume of testes and GSI in experimental rats and the data's were statistically significant (Table 1). Histological analysis of seminiferous tubules showed reduction in number of spermatozoa in control rats than that of experimental rat was observed.^[18] Spermatocytes count showed increased severe reduction in number and is significant. In mammals, spermatogenesis is totally dependent upon testosterone.^[19,20] The following abnormalities were noticed both in the control and experimental groups as described by Oyeyemi et al headless tail, rudimentary tail, curved mid piece, curved tail, looped tail, bent mid piece, tailless head, and bent tail.^[21] The morphological analysis of the spermatozoa of control rats had more number of abnormal spermatozoa than the experimental rats which showed a marked decrease. Further analysis of the spermatozoa count, using Chi-square test was found to be highly significant ($p > 0.001$). The

control rat testes were compared to that of the experimental group of senile rats. The experimental rat testes showed normal in appearance (Fig 2&4) whereas the control senile rats testes damage was observed in 45 % tubules and some tubules seemed to be completely empty without the spermatozoa (Fig 1&3). The diameter of seminiferous tubule showed marked variation in experimental than control group. The Leydig cells were normal but the stroma was considerably reduced in control rats.^[18]

Hamada et al had done a study on concentration of testosterone hormone in different age groups stating that the concentration declines with increasing age.^[1] The testosterone hormone level of experimental rats showed marked variation than that of control. The Leydig cell which found to be normal in experimental rat seminiferous tubule and that was responsible for secretion of testosterone in experimental rats as well as control rats had few Leydig cells with reduced stroma secreting less testosterone hormone. The hormone levels of both groups were statistically significant (Table 1).

CONCLUSION

Herbs are gaining wide importance in the treatment of various chronic ailments, Nowadays researches turned towards herbal trials because of its need to cure various diseases. A preliminary animal study was carried out in albino rats to evaluate the fertility effect of the herb. The *Ionidium suffruticosum* extract administration showed significant positive results in improving various parameters involved in maintaining maleness. Various parameters of the study were analyzed which proved to be more effective in senile rats. Further the qualitative and quantitative analysis of *Ionidium suffruticosum*, alkaloid specificity is still under process.

ACKNOWLEDGEMENT

Authors acknowledge the great help received from the scholars whose articles cited and

included in references of this manuscript. The authors are also grateful to authors / editors / publishers of all those articles, journals and books from where the literature for this article has been reviewed and discussed. Authors are grateful to IJCRR editorial board members and IJCRR team of reviewers who have helped to bring quality to this manuscript.

REFERENCES

1. Alla J Hamada, Aspinder Singh, Ashok Agarwal. Cell phones and their importance on male fertility, fact or fiction. The Open Reproductive Science Journal 2011; 5: 125-127.
2. Ganeriwal S K, Tiwari B V, Reddy B V, Kher J R. Effect of geriforte on male reproductive organs in albino rats. Indian Drugs 1998; (19) 3: 102.
3. Ufaw. The Handbook on the management of laboratory animals. Churchillivingstone Edinburgh, London; 1976. pp.46.
4. Senthil Kumar B, Vijaya Kumar J, Selvaraj R. An Acute Oral Toxicity Study of *Cycas circinalis* and *Ionidium suffruticosum* in Wister Albino Rats, International journal of Pharmaceutical Sciences Review and Research 2012;17(2): 97-100.
5. Senthil Kumar Babu, Panneer Selvi Gopalsamy, Effect of Ceric Sulphate on Gonads of Male Albino Rats, International Journal of Research in Pharmacy and Science 2012; 2 (3): 60-68.
6. Paul Flecknell. Laboratory animal anesthesia, 3rd edition. Elsevier publication; 2009. pp.187.
7. Gay IW. Methods of animal experimentation, Academic Press; London; 1966. pp.54.
8. Senthil Kumar B, Vijaya Kumar J, Effect of *Ionidium Suffruticosum* seeds on Testes of young Albino Rats, International Journal of Pharmacy and Biological Sciences. 2012; 2(3):106-112.

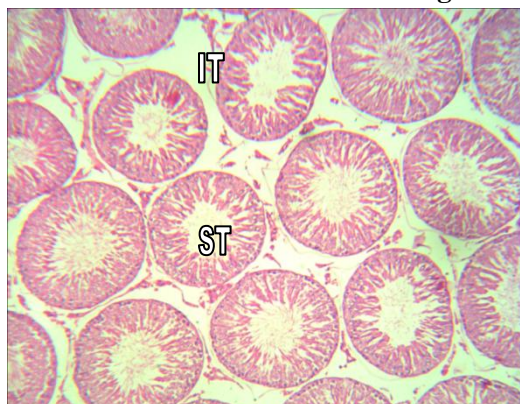
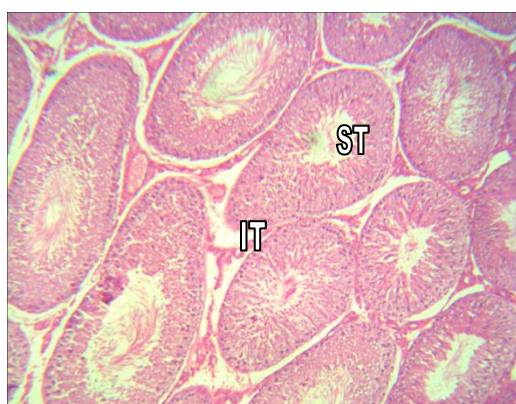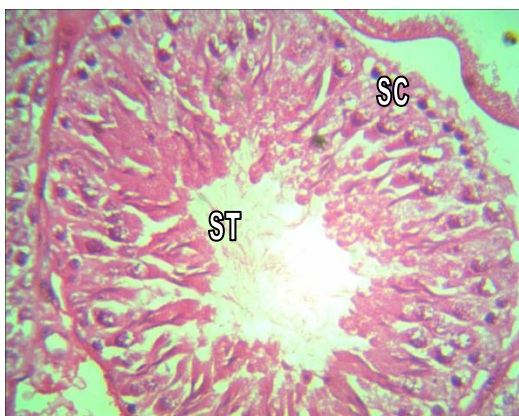
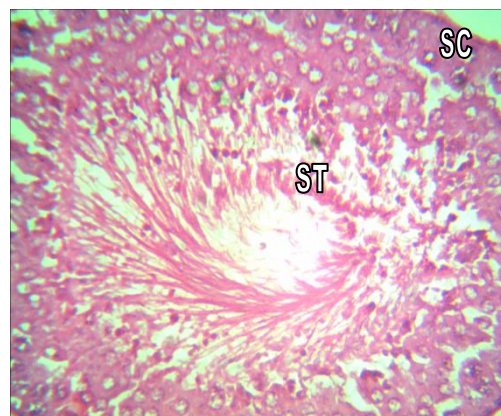
9. Ming Li Hsieh, Shih Tsung Huang, Hsin Chieh Huang, Yu Chen and Yu-Chao Hsu. The reliability of ultrasonographic measurements for testicular volume assessment: comparison of three common formulas with true testicular volume. *Asian Journal of Andrology* 2009; 11: 261–265.
10. Qamar Hamid, LiagatAliminhas, Sadaf Hamid, Anjuman Gal. Influence of cimetidine and bromocriptine on weight of rats and its relation with fertility. *Journal of clinical medicine and research* 2010; 2(2): 015-021.
11. RabiaLatif, Ghulam Mustafa Lodhi, Muhammad Aslam. Effects of amlodipine on serum testosterone, testicular weight and Gonado-Somatic Index in adult rats. *J Ayubcollabhottabad* 2008; 20(4): 8-10.
12. Druby RAB, Wallington EA. *Carleton's Histological technique*, 5th edition, Oxford University press, Newyork, 1980. pp. 140-142, 344-346.
13. Culling CFA. *Handbook of Histopathological and Histochemical techniques*, 3rd edition, press, 1975, pp.49, 213, 491-92.
14. Tung Yang Wing, Kent Christensen. A Morphometric studies on rat seminiferous tubule. *The American Journal of Anatomy* 1982; 165: 13-25.
15. Weibel ER, Bolender RP. *Stereological techniques for microscopy*. A Hayat Ed van Nostrand Reinhold, New York: 237-296.
16. Elias H, Hyde DM. An elementary introduction to stereology (quantitative microscopy). *Am J Anat* 1980; 159: 411-446.
17. Graph pad software, website <http://www.graphpad.com/quickcalcs/ttest1.cfm>
18. Mathur R, ReenaKulshrestha. Restitution of *Ceric sulphate*- induced sterility in rats by Zinc and speman. *J.Sci.Res* 1984; 6(1): 11-13.
19. Pakarainen T F, Zhang S, Makela M. Poutanen I. Huhtaniemi Testosterone replacement therapy induces spermatogenesis and partially restores fertility in luteinizing hormone receptor knockout mice. *Endocrinol.* 2005; 146: 596-606.
20. Wang R, S Yeh, C Tzeng, C Chang Androgen receptor roles in spermatogenesis and fertility: Lessons from testicular cell-specific androgen receptor knockout mice. *Endocrinol. Rev.* 2009 ; 30: 119-132.
21. Oyeyemi MO, oluwatoyin O, AjalaLeigh OO, Adesiji T, Fisayo. The Spermogram of male Wister rats treated with aqueous leaf extract of *veronica amygdalina*: *Folia Veterinaria* 2008; 52(2): 98-101.

Table – 1 Various Parameters of the study

Sl. no	Parameters	Control rats (n = 8) Mean ± SEM	Experimental rats (n = 8) Mean ± SEM
1	Mounting Index(MI)	7.85 ± 1.68	8.43 ± 1.59**
2	Total sexual behavior (TSB)	198.20 ± 0.967	210.30 ± 0.984**
3	Weight of rats (gm)	361.17 ± 1.53	365.33 ± 1.78#
4	Volume of testes (cu.cm)	1.21 ± 0.09	1.38 ± 0.10#
5	Weight of Testes (gm)	1.06 ± 0.02	1.42 ± 0.02**
6	Gonado somatic index (GSI)	0.29 ± 0.01	0.39 ± 0.01***
7	Sperm count (millions/ ml)	27.9 ± 0.33	46.91 ± 0.64***
8	Testosterone hormone level (ng/ml)	1.83 ± 0.16	3.26 ± 0.22***
9	Diameter of seminiferous tubule (µm)	238.89 ± 3.4	276.21 ± 8.6***

*P<0.05, **P< 0.01, ***P<0.001, # - Statistically not significant, n – number of animals, SEM – Standard Error Mean

Histological Analysis of Testes of Albino Rats

**Figure – 1 Control Rat (Testes)****Figure - 2 Experimental Rat (Testes)****Figure - 3 Control Rat (Testes)****Figure - 4 Experimental Rat (Testes)**

ST-Seminiferous tubule , IT-Interstitial tissues, LC- Leydig cells.
ST-Sertoli cells, LC- Leydig cells