

**IJCRR**

Vol 05 issue 09

Section: Healthcare

Category: Research

Received on: 25/03/13

Revised on: 21/04/13

Accepted on: 13/05/13

## **GOLD WEIGHTED EYELID IMPLANT IN POST OPERATIVE FACIAL NERVE PALSY**

Shaila Bangad<sup>1</sup>, Surabhi Chopra<sup>1</sup>, Sham Somani<sup>1</sup>, Y.U. Kelgaonkar<sup>1</sup>, Sachin B. Ingle<sup>2</sup>

Department of ENT, MIMSR Medical college, Latur, MH, India

Department of Pathology, MIMSR Medical college, Latur, MH, India

E-mail of Corresponding Author: dr.sachiningle@gmail.com

### **ABSTRACT**

Lagophthalmos is defined as the inability to close the eyelids completely. This situation may lead to corneal problems such as epithelial defects, stromal thinning, exposure keratitis, bacterial infection, perforation, and blindness. A patient with lagophthalmos due to post operative facial nerve paralysis underwent insertion of a custom-made gold weight implant. After implantation, the patient was able to close her eye and expressed high cosmetic and aesthetic results.

**Keywords :** lagophthalmos, facial nerve palsy, eyelid, gold weight implant

### **INTRODUCTION**

Lagophthalmos is defined as the inability to close the eyelids completely. Orbicularis oculi muscle that closes eyelids is innervated by facial nerve (CNVII). Paresis of the orbicularis oculi muscle leads to diminished blink, lagophthalmos, and impairment of the nasolacrimal pumping system. Lagophthalmos may be the result of the residual effect of seventh cranial nerve damage secondary from congenital (moebius' syndrome), acquired (Bell's palsy, vascular lesions), tumors, iatrogenic (during surgery), trauma, infections, or degenerative diseases (Rubin et al,1986). The blink reflex and lid closing are critical to maintain the ocular health. Each blink spreads the tear film over the ocular surface and allows a continuous layer of moisture. The inability to close the eyelid may lead to corneal problems such as epithelial defects, stromal thinning, exposure keratitis, bacterial infection, perforation, and blindness (Synde et al, 2001).

The prior treatment of lagophthalmos is conservative and symptomatic such as ointments, eye drops, taping, and moisture

chambers (Tuna et al,2008). Surgical intervention may be required in patients who have failed medical therapy or in whom the facial paralysis is not expected to improve. Upper lid loading in the treatment of paralytic lagophthalmos brings out the highest patient satisfaction in lid closing during the day and during sleep as well as in the aesthetic appearance of the lid. When implanted into lid margin, the weight will essentially allow earth's gravity to gently pull the eye to the closed position when the muscles relax.

In this procedure, a gold weight is inserted in the upper eyelid to allow closure by the force of gravity. The presence of the weights seems to contribute to blinking of the eyelids which provides a better aesthetic appearance.

Gold is the preferred material due to its color, specific gravity, and tissue compatibility. Gold weight eyelid implants can elicit a gradually progressive inflammatory response. In at least some cases, local corticosteroid injection may suppress the inflammation and permit retention of the implant (Tremolada et al,2001). Common complications are related to the selection of

wrong weight, and insufficient or excessive correction.

### CASE REPORT

A 22 year old female patient with a history of post operative facial nerve palsy underwent a gold eyelid implant in our department for correction of her lagophthalmos.

The gold piece was given a desired curvature. Three holes were drilled on the gold plate to fix the suture during the surgery. The gold weight

implant was inserted and fixed to the tarsal plate. A protective pad was applied to cover the eyelid. Patient's complete eyelid closure and restoration of blink reflex were obtained at postoperative examination. Corneal irritation symptoms were not observed after the procedure. After the healing phase of the edema on the eyelid, the patient was instructed to exercise to close her eyelid manually. The patient was able to close her eye and pleased with the cosmetic and esthetic results after 2 years control trial.

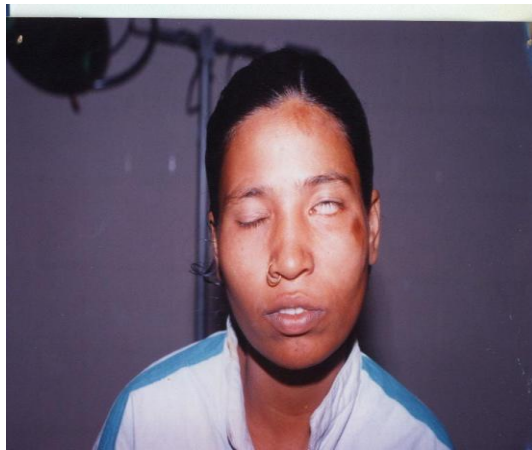

Fig 1: Preoperative photograph of the patient

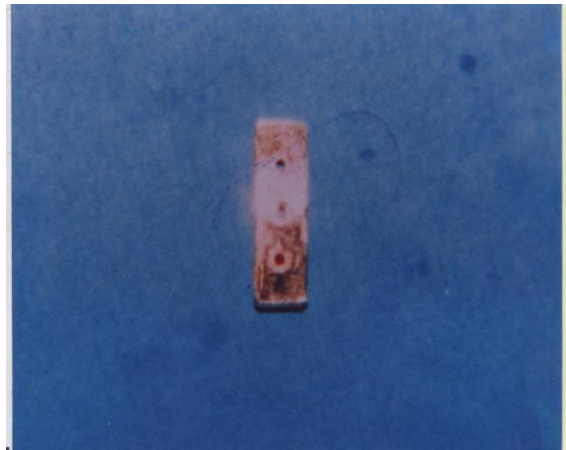


Fig 2: Picture of gold weighted eye lid implant

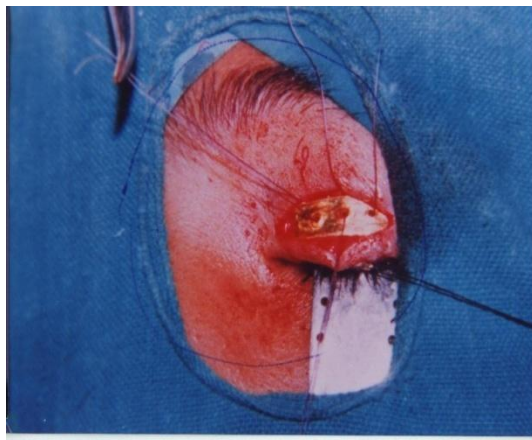

Fig 3: Operative photograph of insertion of implant

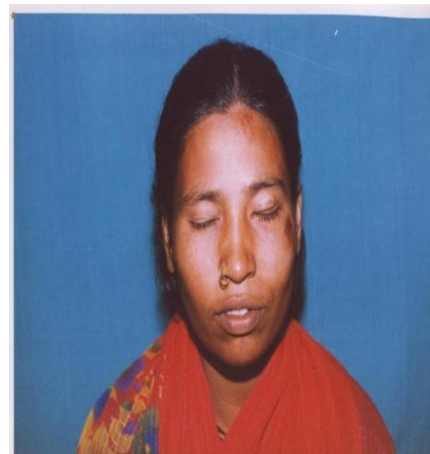

Fig 4: Post operative photograph

## DISCUSSION

Gold weight implantation is the most commonly used static procedure and method for surgical correction of paralytic lagophthalmos. Other mechanical techniques for reanimating lid closure are palpebral springs, encircling the upper and lower eyelids with silicone or fascia lata, and temporalis muscle transfer (Choo et al, 2000). Although other materials are also used, gold weights are frequently preferred because of gold's high specific gravity, inertness to the body and malleability. Especially platinum weights should be used in patients with suspected gold allergy (Choi et al, 2004).

The use of gold weight eyelid implants is certainly a desirable option for treatment of patients suffering from lagophthalmos, but it is not always successful or may not give the desired aesthetic result due to the thickness of the prefabricated implants and the anatomical structures of the eye. There are distinct anatomic differences between the Caucasian and Asian eyelids, which dictate the overlying aesthetic differences (Cline et al, 1997). Commercially manufactured gold implants are available in several weights and are usually used but may create a "brick-like" appearance within the eyelid. Custom-made weights that produce a much more aesthetic result can be fabricated by the dental professionals.

The gold weight trial procedure was considered a success when postoperative lagophthalmos met the predefined preoperative success criteria (minimum 50% reduction in lagophthalmos without induction of >2 mm ptosis) and was considered a failure when the reduction in the lagophthalmos did not reach 50% of the preoperative value (Grisius et al, 1993).

Adequate preoperative evaluation is necessary to determine optimum size, weight, and position of the gold implant. The most common complications result from inappropriate gold weights. The insufficient gold weight is not effective for closing the eyelid; contrary

excessive estimation leads to unaesthetic appearance and ptosis of the eyelid. However, it is also frequently associated with certain complications like ulceration, migration, extrusion, etc. At the present case, care was taken to find the appropriate weight before the operation. As a result, the selected weight and curvature of the gold implant was unique to patient, and there were no complications during the follow-up period of at least 2 years (Rubin et al, 1986).

Kelly and Sharpe suggested that the implants must be fabricated in perforated design to allow tissue penetration and to prevent migration. It was also reported that gold implants which do not adapt the slope of cornea cause astigmatism. Our patient did not complain of any visual discomfort. Because of the aforementioned complications due to fabricated weights, we preferred a custom-made gold weight implant (Somnez et al, 2008).

The estimated weight of the implant from the trials on the skin of the upper lid fails to obtain the expected eye closure outcomes after surgical implantation on the tarsal plate. The results show that an addition of 0.2 g to the gold weight estimated in the trial is required to achieve a similar closure of the eye by means of the gold implant on the tarsal plate (Tuna et al, 2008).

Smellie suggested 0.75 to 1.0 g of lid loading for most effective eyelid closure, whereas Gilbard and Daspit concluded that a much heavier weight (1.2 to 2.6 g) is required to achieve complete lid closure. According to Aggarwa et al the median predicted ideal gold weight was 1.2 g (range, 1.0 to 2.0 g). In this case the gold weight was 1.3 g (Aggarwal et al, 2007).

Usually to fabricate the gold implant at the determined weight, the density of the gold and the weight of the wax pattern are helpful for calculation.

## CONCLUSION

Use of gold weighted eye lid implant is a desirable option for patients with post operative lagophthalmos due to facial nerve paralysis. In our case we received a 50% correction in lagophthalmos without induction of ptosis. Use of proper weight implant and its adequate fabrication are important as discussed in the article.

## ACKNOWLEDGEMENT

We greatly acknowledge the help received from the scholars whose articles cited and included in references of this manuscript. The authors are also grateful to authors / editors / publishers of all those articles, journals and books from where the literature for this article has been reviewed and discussed. Authors are specially thankful to Dr Sachin B Ingle, IJCRR editorial board members and IJCRR team of reviewers who have helped to bring quality to this manuscript.

## REFERENCES

1. Aggarwal E, Naik MN, Honavar SG. Effectiveness of gold weight trial approach in predicting ideal weight for lid loading in facial palsy : A prospective study. *Am J ophthalmol*. 2007; 143: 1009-1012
2. Coho PH, Carter SR, Seiff SR. Upper eyelid gold weight implantation in the Asian patient with facial paralysis. *Plast Reconstr Surg*. 2000; 105:855–859. [[PubMed](#)]
3. Choi M, Driscoll CF. Fabrication of a custom eyelid implant prosthesis: a clinical report. *J Prosthodont*. 2004; 13:101–103. [[PubMed](#)]
4. Cline D, Hofstetter HW. *Dictionary of visual science*. 4th ed. Boston: Butterworth-Heinemann; 1997.
5. Grisius MM, Hof RL. Treatment of lagophthalmos of the eye with a custom prosthesis. *J Prosthet Dent*. 1993; 70:333–335. [[PubMed](#)]
6. Rubin LR, Lee GW, Simpson RL. Reanimation of the long-standing partial facial paralysis. *Plast Reconstr Surg*. 1986; 77:41–49. [[PubMed](#)]
7. Sonmez A, Ozturk N, Durmus N, Bayramicli M, Numanoglu A. Patients' perspectives on the ocular symptoms of facial paralysis after gold weight implantation. *J Plast Reconstr Aesthet Surg*. 2008; 61:1065–1068. [[PubMed](#)]
8. Synder MC, Johnson PJ, Moore GF. Early v/s late gold weight implantation for rehabilitation of paralyzed eye. *Laryngoscope*. 2001; 112: 1213-1223
9. Tremolada C, Raffiani M. Custom weighted gold lid implants for correction of lagophthalmos. *J Craniomaxillofacial Surg*. 2001; 121: 1234-1456
10. Suleyman Hakan Tuna, Hasan Onder Gumus, Nur Hersek. Custom made gold implant for management of lagophthalmos : A case report. *Euro J Dent*. 2008; 12:23-34.