



**IJCRR**

Vol 06 issue 06

Section: Healthcare

Category: Research

Received on: 12/12/13

Revised on: 15/01/14

Accepted on: 17/02/14

## A STUDY OF MUSCULAR BRANCHES OF RADIAL NERVE: SIGNIFICANCE IN TREATMENT OF HUMERAL FRACTURE

Bharati Prabhakar Nimje<sup>1</sup>, P. S. Bhuiyan<sup>2</sup>

<sup>1</sup>Department of Anatomy, TN Medical College, Mumbai Central, MH, India

<sup>2</sup>Department of Anatomy, Seth GS Medical College, Parel, Mumbai, MH, India

E-mail of Corresponding Author: nimjebharati@gmail.com

### ABSTRACT

The most common indications for surgical exposure of the radial nerve, along its course from axillary fossa to proximal part of forearm is repair of its open or closed traumatic injuries, surgical removal of nerve tumors and for treatment of entrapment neuropathies. Purpose of this work was to analyze topographical relations of radial nerve in the arm with reference to easily detectable anatomical landmarks. 114 upper limbs from 57 formalin-fixed cadavers were dissected meticulously to expose the radial nerve from its origin to its termination. The distance of origin of radial nerve and origin of branch to long head of triceps brachii and branch to medial head of triceps brachii originating in axilla is measured from tip of coracoid process of scapula. The distance of origin of branch to lateral head of triceps brachii and branch to medial head of triceps brachii originating in radial groove were measured from medial epicondyle of humerus. Distance of origin of branch to brachioradialis, branch to extensor carpi radialis longus and branch to anconeus were measured from the lateral epicondyle of humerus. Although efforts have been made by several authors to obtain precise anatomical data regarding the course of radial nerve and its topographical relations, measurements of radial nerve position with reference to reliable anatomical landmarks in the arm are seldom reported. This data will be useful for understanding the effect of entrapment or traumatic lesions along the course of radial nerve, for choosing the correct procedures and for allowing safe positioning of fixation implants.

**Keywords:** Radial nerve, triceps brachii, radial groove, medial epicondyle, topography, entrapment

### INTRODUCTION

Nature created the radial nerve to enable us to perform a variety of tasks with our arms, ranging from riding a scooter to performing complicated surgical procedure, not to mention various day to day activities. Anatomical knowledge is required for performing physical examination and diagnostic tests, interpreting their results and instituting treatment, particularly surgical procedures<sup>1</sup>.

Radial nerve is the one which comes in direct contact with humerus and that is why it is prone to get damaged in fracture of shaft of humerus<sup>2</sup>. As a treatment of humeral fracture, either a closed manipulation or open reduction with internal

fixation is done<sup>2</sup>. Often, in orthopedic surgery, the radial nerve has to be exposed in order to permit the positioning of fixation implants for humeral fractures. The common operative exposure of the radial nerve in this area is the posterior approach, with the patient in lateral decubitus or in prone position. For open reduction, it is mandatory to know all the branches of radial nerve so as to save the movements of elbow and wrist. As Dr. Bergman indicates, it is only through human dissection that gross anatomical variation is really appreciated<sup>3</sup>.

Although bony structures may be altered in some pathological conditions like fractures and dislocations, anatomical landmarks may be useful

for allowing surgeons to accurately identify the radial nerve, at least when normal anatomy is preserved, thus decreasing the likelihood of iatrogenic damage. Anatomical landmarks used in this study were tip of coracoid process of scapula, lateral and medial epicondyles of humerus. The parameters included in this study analyzed the topographical relationship of the radial nerve and its branches with that of the bony landmarks.

In the arm, the radial nerve can be frequently injured due to fractures of the distal half of the humerus or iatrogenically after posterior surgery for open reduction and internal fixation of humeral fractures<sup>4, 5</sup>. Early exploration is advised by many authors for humeral shaft open fractures, spiral fractures and longitudinal fractures of the distal third of the humerus. Chronic radial nerve compressions at different sites at the arm are less frequently noted<sup>4</sup>.

## MATERIALS AND METHODS

The present study was done on 114 upper limbs of 57 cadavers. The cadavers were embalmed with 10% formalin. The upper limb in each supine cadaver was abducted and laterally rotated. Skin was incised from manubrium sterni to both xiphoid process of sternum as well as acromion process of scapula. Further, the skin was incised from xiphoid process extending upwards and laterally, along the floor of axilla, to the middle of the arm. Incision was further extended from middle of the arm up to apex of cubital fossa. The skin and superficial fascia were reflected from the deep fascia by blunt dissection. The deep fascia was then incised to expose muscles. The pectoralis major and minor muscles were reflected laterally to expose axilla. The axilla was dissected by removing loose connective tissue and fat. The axillary fascia was then incised and lymph nodes were removed to expose the cords of brachial plexus. The coracobrachialis and short head of biceps brachii muscle were then exposed. Radial nerve was identified. The long head of triceps brachii was exposed. Branches of radial nerve in

axilla were identified and measured from the tip of the coracoid process by bisector and scale. (Figure 1)

The cadaver was then pronated to expose the posterior aspect of the arm. The skin and superficial fascia were reflected from deep fascia by blunt dissection. The deep fascia over triceps brachii was incised. The lateral and medial heads of triceps brachii were identified. The radial nerve passes in between the two heads. To expose the radial nerve, the lateral head of triceps brachii was cut and reflected. Muscular branches of radial nerve were identified and the origin of each branch was measured from medial epicondyle by thread and scale. Radial nerve pierces the lateral intermuscular septum to come into anterior compartment of arm. (Figure 2)

The cadaver was again put in supine position with arm abducted to 90°. The radial nerve was identified in-between brachialis and brachioradialis. The branches to brachioradialis, extensor carpi radialis longus muscles were identified and their origin from lateral epicondyle was measured by bisector and thread. (Figure 3)

## RESULTS

### 1. Branch to the long head of triceps brachii (Table 1)

The mean distance of the origin of first branch to long head of triceps from the tip of the coracoid process in all 57 specimens of left side was found to be 69.4mm ranging from 46mm to 96mm and that of right side was found to be 75.9mm ranging from 51mm to 99mm.

### 2. Branch to the medial head of triceps brachii

The mean distance of the origin of first branch to medial head of triceps from the tip of the coracoid process in all 57 specimens of left side was found to be 77.2mm ranging from 9mm to 104mm and that of right side was found to be 77.8mm ranging from 50mm to 108mm. (Table 2 a)

The mean distance of the origin of first branch to medial head of triceps from the medial epicondyle

in all 57 specimens of left side was found to be 189.1mm ranging from 139mm to 220mm and that of right side was found to be 192.8mm ranging from 153mm to 225mm. (Table 2 b)

### **3. Branch to lateral head of triceps brachii (Table 3)**

The mean distance of the origin of first branch to lateral head of triceps from the tip of the coracoid process in all 57 specimens of left side was found to be 199mm ranging from 148mm to 246mm and that of right side was found to be 201mm ranging from 152mm to 225mm.

### **4. Branch to brachialis (Table 4)**

The mean distance of the origin of first branch to brachialis from lateral epicondyle in 7 specimens of left side was found to be 51.4 mm ranging from 43mm to 59mm and that in 6 specimens of right side was found to be 55.5 mm ranging from 49 mm to 63 mm.

### **5. Branch to brachioradialis (Table 5)**

The mean distance of the origin of first branch to brachioradialis from lateral epicondyle in all 57 specimens of left side was found to be 44.4mm ranging from 24mm to 89mm and that of right side was found to be 45.1mm ranging from 28mm to 72mm.

### **6. Branch to extensor carpi radialis longus (Table 6)**

The mean distance of the origin of first branch to extensor carpi radialis longus from lateral epicondyle in all 57 specimens of left side was found to be 41mm ranging from 20mm to 85mm and that of right side was found to be 42mm ranging from 22mm to 78mm.

### **7. Branch to anconeus (Table 7)**

The mean distance of the origin of branch to anconeus from lateral epicondyle in all 57 specimens of left side was found to be 67.2mm ranging from 34mm to 124mm and that of right side was found to be 68.3mm ranging from 42mm to 171mm.

## **DISCUSSION**

As per Sunderland, all the branches to triceps brachii were distributed through axilla and radial groove, in all the specimens<sup>6</sup>. The motor branches to triceps brachii did not originate only in the axilla or only in the radial groove. The present study also confirms the same findings.

As per the study done by de Seze et al., branch supplying the long head of triceps brachii arose from the axillary nerve but not from the radial nerve unlike in the present study, the branch to long head of triceps brachii arose from the radial nerve only<sup>7</sup>.

As per Sunderland, anconeus was supplied by the branch to medial head of triceps brachii which descended in the substance of that muscle<sup>6</sup>. In the present study a branch to medial head of triceps was given from the radial nerve in the radial groove which descended in the substance of medial head of triceps brachii. This branch then divided into two branches nearer to the elbow joint one of which supplied the anconeus muscle and the other one supplied the elbow joint. According to the present study, branch given to the medial head of triceps divided 50-100mm proximal to the lateral epicondyle of humerus.

According to Sunderland, in half of the specimens, the lateral head of triceps brachii was innervated before its medial head regardless of the order of branching<sup>6</sup>. In majority of these cases, the branch to the lateral head left the nerve before that to the medial head<sup>6</sup>. Contradictory to it in the present study, branch to the medial head of triceps brachii arose before that of the lateral head; in the axilla. But if only radial groove was considered; Sunderland's statement was comparable to the present study in which branch to the lateral head of triceps brachii arose from radial nerve trunk proximal to that of the medial head in the radial groove. Both of them ran along the sides of the parent trunk of radial nerve in radial groove as collaterals<sup>6</sup>.

As per Sunderland; in half of the specimens, the lateral head of triceps brachii were supplied by branches leaving the nerve in radial groove. In one third of the specimens, the medial head of triceps brachii were supplied by branches leaving the nerve in radial groove. Majority of them were in contact with the bone<sup>6</sup>. As per Linell, other than the branch to medial head of triceps brachii which arose at the upper limit of radial groove, no other muscular branch arose while the main trunk of radial nerve was in the groove<sup>6</sup>. In the present study, the branch to the medial head and lateral head of triceps brachii arose in the radial groove. Findings in the present study matched with Sunderland's findings but it differed from the findings of Linell.

According to Sunderland, the muscle innervated by the nerve in the furrow commonly received several branches. No branch from the radial nerve in the furrow left at a higher level than 60mm above the lateral epicondyle except for the branch to brachialis<sup>6</sup>. In the present study, it was seen that branches to brachioradialis arose at a distance more than 60mm above the lateral epicondyle of the humerus in 7% of specimens. Branches to extensor carpi radialis longus arose at a distance more than 60mm above the lateral epicondyle of the humerus in 2% of specimens. As per Sunderland, multiple branches were present in the intermuscular furrow; highest and lowest were destined for brachioradialis and extensor carpi radialis brevis respectively<sup>6</sup>. Observations of the present study showed that though the highest branches were destined for brachioradialis, lowest were destined for extensor carpi radialis longus and not extensor carpi radialis brevis.

According to the study done by Sunderland, the mean distance between the site of origin of branch to brachialis muscle and lateral epicondyle of humerus was 59 mm which matched with the present study which observed it to be 54 mm<sup>6</sup>. According to the study done by Blackburn et al, the mean distance of origin of the branch to brachialis muscle was 69 mm with a range of 45-

100 mm<sup>8</sup>. The present study observations differed from his study with findings of the mean of the distance being 54 mm and the range being 43-63 mm. The present study matched with the study of Frazer et al who stated the mean distance between the site of origin of branch to brachialis muscle and lateral epicondyle of humerus to be 61 mm with a range of 21-72 mm<sup>9</sup>. (Table 8)

## CONCLUSIONS

The average distance between the site of origin of the branch to long head of triceps brachii and the tip of the coracoid process of scapula was found to be 69.4mm +/- 12.56 mm on left side while 75.9mm +/- 10.48 mm on right side.

The average distance between the site of origin of the branch to medial head of triceps brachii given in the axilla and the tip of the coracoid process of scapula was found to be 77.2mm +/- 16.11 mm on left side while 77.8mm +/- 11.83 mm on right side. The average distance between the site of origin of the medial head of triceps brachii and the medial epicondyle of the humerus was found to be 189.1mm +/- 18.7 mm on left side while 192.8mm +/- 16.33 mm on right side.

The average distance between the site of origin of the branch to lateral head of triceps brachii and the medial epicondyle of the humerus was found to be 198.6mm +/- 18.73 mm on left side while 201.1mm +/- 16.03 mm on right side.

The average distance between the site of origin of the branch to brachialis and the lateral epicondyle of humerus was found to be 51.4mm +/- 5.32 mm on left side and 55.5mm +/- 4.97 mm on right side. The average distance between the site of origin of the branch to brachioradialis and the lateral epicondyle of the humerus was found to be 44.4mm +/- 11.17 mm on left side while 45.1mm +/- 9.3 mm on right side.

The average distance between the site of origin of the branch to extensor carpi radialis longus and the lateral epicondyle of the humerus was found to be 41.4mm +/- 12.31 mm on left side while 41.7mm +/- 10.26 mm on right side.

The average distance between the site of origin of the branch to anconeus and the lateral epicondyle of the humerus was found to be 67.2mm +/- 16.44mm on left side while 68.3mm +/- 19.75 mm on right side.

The present study provides reliable and objective data for surgical anatomy of the radial nerve, obtained from dissection of embalmed cadavers, which should always be kept in mind by surgeons approaching to the surgery of the arm, in order to avoid iatrogenic injuries. Awareness of the position of the branches of radial nerve would assist the surgeon to better orientate during surgery and thus reduce the surgical complications. Thus this study could be of help for various surgical approaches of open reduction of humeral fracture like anterolateral approach and posterior approach.

**REFERENCES**

1. Sinnatamby C S. In: Sinnatamby C S, editor. Last’s anatomy: regional and applied. 11<sup>th</sup> ed. London: Churchill livingstone; 2006, vii.
2. Maheshwari J. Injuries around shoulder, fracture humerus. In: Maheshwari J, editor. Essential orthopedics. 3<sup>rd</sup>Ed. New Delhi: Mehta publishers; 2002; 72-78.
3. Bergman R A. Thoughts of human variations. Cilm. Anat. 2011; 24: 938-40.
4. Artico M, Telera S, Tiengo C, Stecco C, Macchi V, Porzionato A, Vigato E, Parenti A, De Caro R. Surgical Anatomy of the Radial

Nerve at the Elbow. J. Surg. Radiol. Anat. 2009; 31: 101-106.

5. de Seze M P, Rezzouk J, de Seze M, Uzel M, Lavignolle B, Midy D, Durandeu D. Does the motor branch of the long head of triceps brachii arise from the radial nerve? An anatomic and electromyographic study. SurgRadiol Anat. 2004; 26:459-46.
6. Sunderland S. The Radial Nerve- Anatomical and Physiological Features. In: Sunderland S, editor. Nerve and Nerve Injuries, Second ed. Edinburgh: Churchill Livingstone; 1978; 802-819.
7. Guse T R, Osrtum R F. The surgical anatomy of the radial nerve around the humerus. Clin. OrthopRelatRes. 1995; 320:149-153.
8. Blackburn SC, Wood CPJ, Evans DJR, Watt DJ. Radial nerve contribution to brachialis in the UK Caucasian population: position is predictable based on surface landmarks. Clin. Anat. 2007; 20:64-67.
9. Frazer E A, Hobson M, McDonald S W. The distribution of the radial and musculocutaneous nerves in the brachialis muscle. Clin. Anat. 2007; 20: 785-89.

**TABLES**

**Table 1: Origin of branch to the long head of triceps brachii from tip of coracoid process**

Side	No. of specimens	Mean (mm)	SD	Range (mm)
Left	57	69.4	12.56	46-96
Right	57	75.9	10.48	51-99

**Table 2 (a): Origin of branch to the medial head of triceps brachii from tip of coracoid process in axilla**

Side	No. of specimens	Mean (mm)	SD	Range (mm)
Left	57	77.2	16.11	9-104
Right	57	77.8	11.83	50-108

**Table 2 (b): Origin of branch to the medial head of triceps brachii from medial epicondyle in radial groove**

Side	No. of specimens	Mean (mm)	SD	Range (mm)
Left	57	189.1	18.70	139-220
Right	57	192.8	16.33	153-225

**Table 3: Origin of branch to the lateral head of triceps brachii from medial epicondyle**

Side	No. of specimens	Mean (mm)	SD	Range (mm)
Left	57	198.6	18.73	148-246
Right	57	201.1	16.03	152-225

**Table 4: Origin of branch to brachialis from lateral epicondyle**

Side	No. of specimens	Mean (mm)	SD	Range (mm)
Left	7	51.4	5.32	43-59
Right	6	55.5	4.97	49-63

**Table 5: Origin of branch to brachioradialis from lateral epicondyle**

Side	No. of specimens	Mean (mm)	SD	Range (mm)
Left	57	44.4	11.17	24-89
Right	57	45.1	9.3	28-72

**Table 6: Origin of branch to extensor carpi radialis longus from lateral epicondyle**

Side	No. of specimens	Mean (mm)	SD	Range (mm)
Left	57	41.4	12.31	20-85
Right	57	41.7	10.26	22-78

**Table 7: Origin of branch to anconeus from lateral epicondyle**

Side	No. of specimens	Mean (mm)	SD	Range (mm)
Left	57	67.2	16.44	34-124
Right	57	68.3	19.75	42-171

**Table no. 8: Distance between the site of origin of branch to brachialis muscle and lateral epicondyle of humerus (measured in mm)**

Sunderland 6		Blackburn et al 8		Frazer et al 9		Present study	
Mean	Range	Mean	Range	Mean	Range	Mean	Range
59	15-88	69	45-100	61	20-72	54	43-63



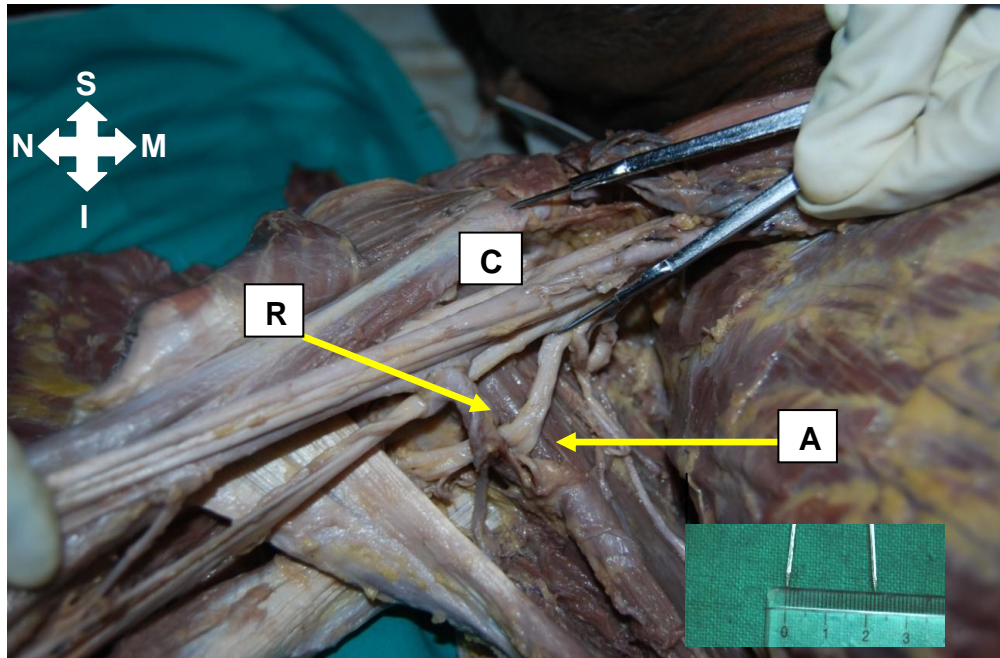


Figure 1: Illustration showing measurement of the distance between the tip of coracoid process of scapula and origin of radial nerve (C- Coracoid process of scapula, R- Radial Nerve, A- Axillary Nerve)


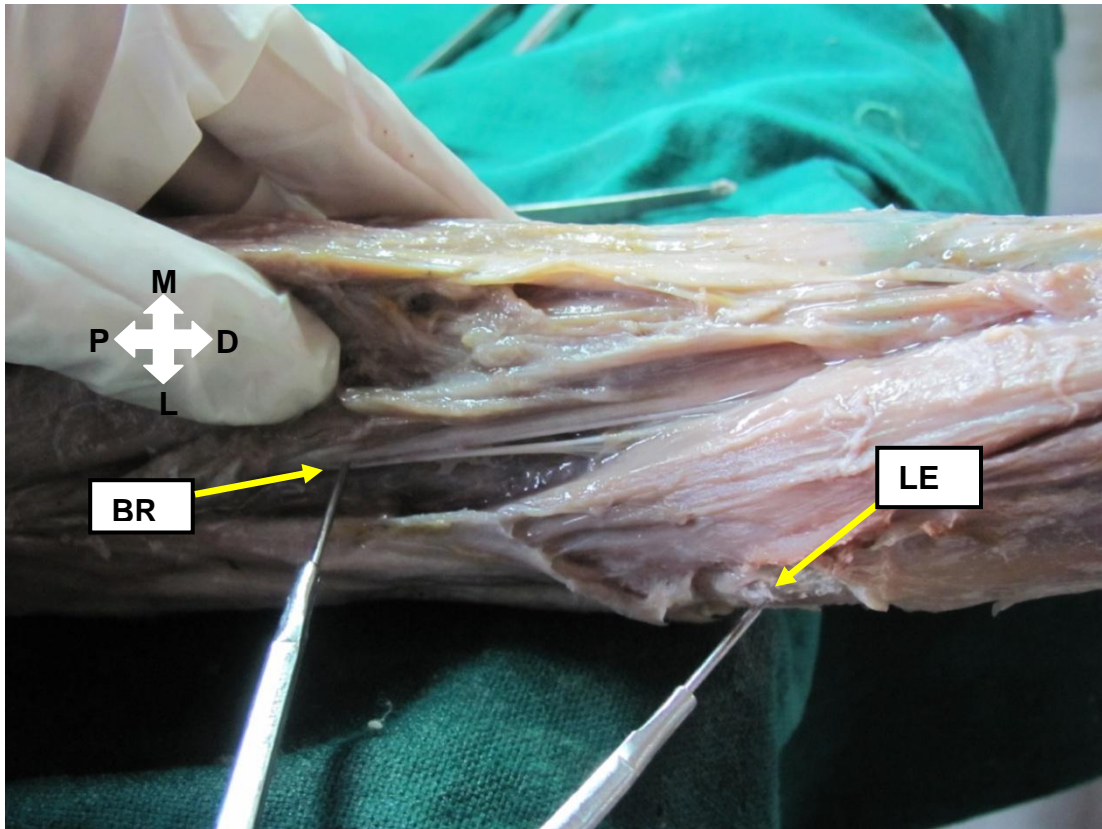


Figure 2: Illustration showing measurement of the distance between branch to long head of triceps brachii and medial epicondyle of humerus (LH- Long head of triceps brachii, ME- Medial epicondyle)



**Figure 3:** Illustration showing measurement of the distance between branch to brachioradialis and lateral epicondyle of humerus (BR- Branch to Brachioradialis, LE- Lateral epicondyle)