



**IJCRR**  
Vol 05 issue 02

Section: Healthcare  
Category: Case Report  
Received on: 13/12/12  
Revised on: 03/01/13  
Accepted on: 22/01/13

## TUBULO-VILLOUS ADENOMA OF FIRST PART OF DUODENUM-AN UNUSUAL PRESENTATION

Vishwas Johri<sup>1</sup>, Syed Javed Arshi<sup>2</sup>

<sup>1</sup>Department of General Surgery, R.N.T. Medical College and Associated Group of Hospitals, Udaipur, India

<sup>2</sup>Department of Pathology, Geetanjali Medical College and Hospital, Udaipur, India

E-mail of Corresponding Author: vishwas@gmail.com

### ABSTRACT

Tubulo-villous tumours of the duodenum are rare tumours which account for less than 1% of duodenal neoplasms, 88% of which are located in the second part of duodenum. The remaining 12% are equally distributed in first and third part of the duodenum [1, 2]. A high rate of malignant transformation complicates management with surgical treatment options ranging from wide local excision to radical pancreaticoduodenectomy [1]. A case of duodenal villous adenoma of the first part of duodenum presenting with vague generalized abdominal pain, nausea and weight loss is reported because of its rarity.

**Keywords:** Tubulo-Villous adenoma, duodenal tumour

### INTRODUCTION

Neoplastic growth in the small intestine is relatively uncommon. Its incidence is usually one-tenth that of a similar lesion of the colon. According to prospective endoscopic studies on elevated lesions of the duodenum, the incidence of duodenal adenoma in all patients referred to diagnostic endoscopy was only 0.4% [3] Tubulo-villous adenomas of the duodenum are rare tumours comprising less than 1% of duodenal neoplasms [1,3]. The widespread use of upper gastrointestinal endoscopy has resulted in more frequent reporting of patients with duodenal adenomas. The clinical presentation is variable, with duodenal obstruction a late feature of large tumours. The coexistence of malignancy, in 21% to 53% of tumors [1, 4] complicates surgical management. Various surgical procedures, ranging from simple local excision to radical pancreatic duodenectomy are done depending on the case per se [5].

### Case Report

A 35-year old female presented with a 6-month history of vague abdominal pain, nausea, sour eructation and decreased appetite. Abdominal pain was diffuse in nature and spread all over the abdomen. The pain was mild to moderate in nature; simultaneously patient also developed sensation of nausea though it never leads to an episode of vomiting. She also had loss of appetite. She received treatment for acid peptic disease (APD), without any relief for 4 months. There was no history of dysphagia, heart burn, blood in stools or alteration of bowel habits. Her routine clinical examination was unremarkable. Her blood counts, urine and stool examination was normal. The stool was negative for occult blood. She was HIV negative. Abdominal sonography was normal. Upper GI endoscopy showed a polypoid mass in the first part of duodenum (Fig.1). Subsequently CT scan of abdomen was done. It revealed well defined round nonenhancing isodense filling defect measuring 17 × 18 × 14 mm on the medial aspect

of the first part of duodenum. No other lesion was noted in any of the bowel loops. Lower GI endoscopy was normal. A provisional diagnosis of solitary duodenal polyp was made.

The patient was taken up for laparotomy. Intraoperative a soft mass was felt in first part of duodenum. Duodenotomy was done, a papillomatous mass was found, it was excised en-bloc from the base. Then Heineke-Mikulicz pyloroplasty was done.

Histopathologic examination revealed a polypoid tumour with numerous branching villi (Fig.2). These were lined by long columnar epithelium with nuclei showing stratification at places. Underlying lamina propria showed hyperplastic Brunner's glands (Fig.3) and slight mucosal inflammation. There was no pathologic evidence of H pylori infection in stomach and duodenum. The tubulo-villous glands were positive for PAS. It was diagnosed as tubulo-villous adenoma of first part of duodenum.

The patient did well postoperatively and was discharged on 10th postoperative day. The patient has been followed up by doing upper GI endoscopy at 6 monthly intervals to look for any recurrence. The patient remains disease free after 4 years.

## DISCUSSION

Villous tumor of the duodenum (VTD) was first described by Perry in 1893 as a broad-based cauliflower-like mass that he referred to as a duodenal papilloma. These lesions are relatively uncommon with only 73 cases reported by Komorowski and Cohen in a 1981 review [5, 6]. Pathologic descriptions have included the terms villous adenoma, villous papilloma, papillary adenoma, tubulovillous adenoma, and villoglandular polyp [5]. The male: female ratio was 1:1, with a mean patient age of 60 years (range: 29-81 years) [2].

Duodenal villous adenomas tend to be large lesions. In a previous review, 22 of 23 villous adenomas were greater than 3 cm in diameter. As

small VTD can easily be missed by barium swallow examinations, today the most useful and accurate diagnostic tool is probably fiberoptic endoscopy with full visualization of the duodenum which enables both visual identification and biopsy of the tumour. The other methods that can be used in diagnosis and staging are ERCP, USG, CT and endoscopic USG [7].

88% of the adenomas are found in the second portion of the duodenum while remaining 12% are equally distributed in first and third part of duodenum [2]. The most frequent presenting symptoms are jaundice, weight loss, epigastric pain, melena or guaiac+ stool, partial intestinal obstruction or may remain asymptomatic. Other less frequent symptoms include diarrhoea, anaemia, fatigue, fever (secondary to cholangitis from biliary obstruction), and recurrent episodes of pancreatitis. The high incidence of malignancy in villous lesions of the duodenum as well as the frequent involvement of the ampulla of Vater has resulted in considerable controversy regarding proper management. A 21-53% rate of cancer in villous adenomas of the duodenum has been reported in duodenal villous adenomas and much less in tubulo villous and tubular adenomas [1, 4, 7]. VTD may occur in most of the patients with Gardner's syndrome and FAP. Polyps in the duodenum occur in 40-91% of FAP patients, and are true dysplastic lesions at risk of cancer. Peri ampullary carcinoma is now the leading cause of death after proctocolectomy in patients with FAP which is affecting up to 12% of patients. For these reasons patients with FAP should have routine Upper GI endoscopy [7]. Based on this data our patient was evaluated and no FAP was found. We concur with the opinion of others who have recommended that all villous adenomas of the duodenum be considered potentially malignant until proven otherwise. Depending on the localization, extension of tumour endoscopic snare excision or ablation, local submucosal excision, full thickness excision, pancreas sparing duodenectomy and pancreaticoduodenectomy

(PD) is recommended. Complete excision is mandatory though opinions differ as to the best method of resection.

### CONCLUSION

Tubulo-villous adenomas of the duodenum are rare tumours comprising less than 1% of duodenal neoplasms. But with widespread and increased availability of upper gastrointestinal endoscopy their incidence is bound to increase.

In our opinion, endoscopically obtained tissue biopsy should guide the management protocol in the adenomas of the first part of duodenum as the distance from papilla of Vater endows them with a wider margin of safety. If malignant transformation has not taken place yet, then complete local excision followed by biannual endoscopic examination to rule out recurrence remains the best approach as it preserves the functional integrity. Even in selected cases with dysplasia or carcinoma in situ complete local excision may be tried before resorting to a radical procedure like pancreaticoduodenectomy.

### ACKNOWLEDGEMENT

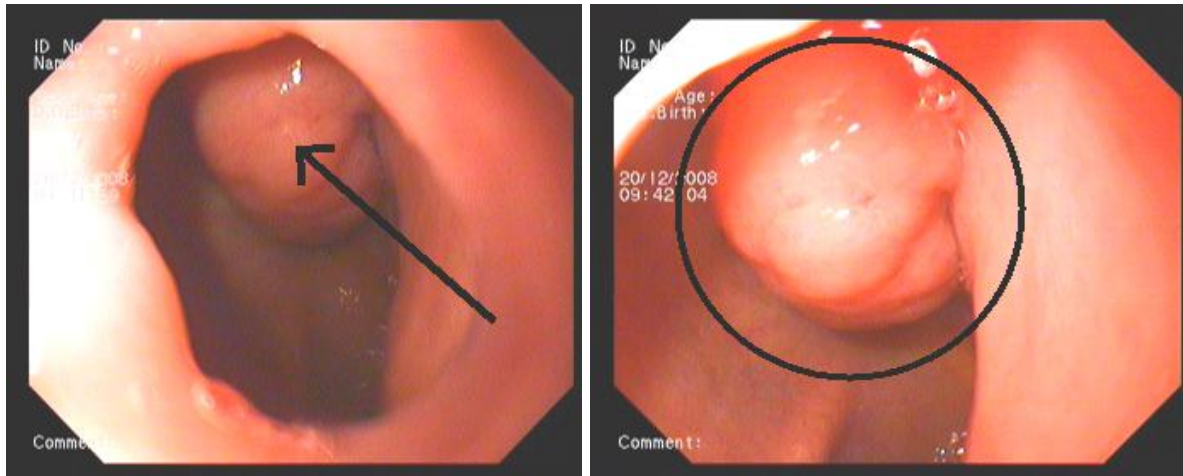
Authors acknowledge the immense help received from the scholars whose articles are cited and included in references of this manuscript. The authors are also grateful to authors / editors / publishers of all those articles, journals and books from where the literature for this article has been reviewed and discussed.

### Conflict of interest

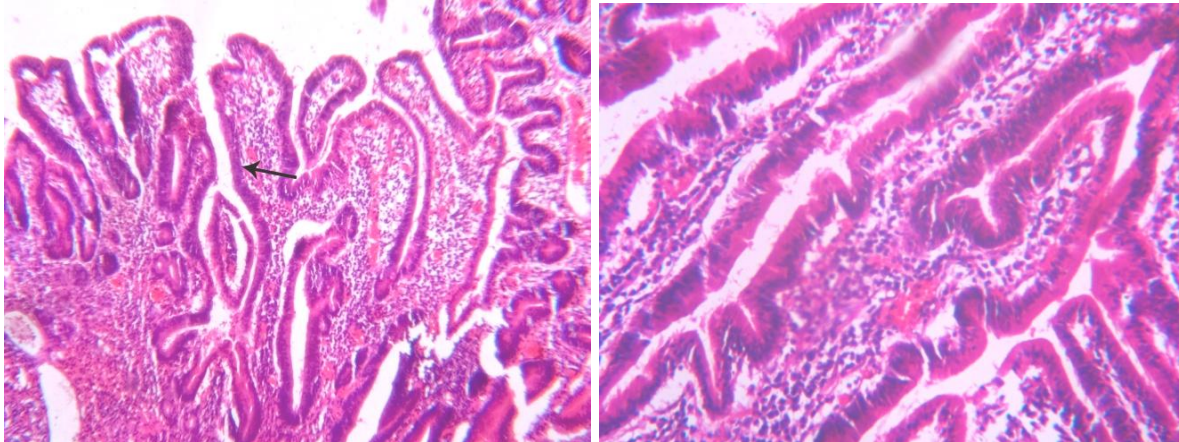
The authors report no conflict of interest.

### REFERENCES

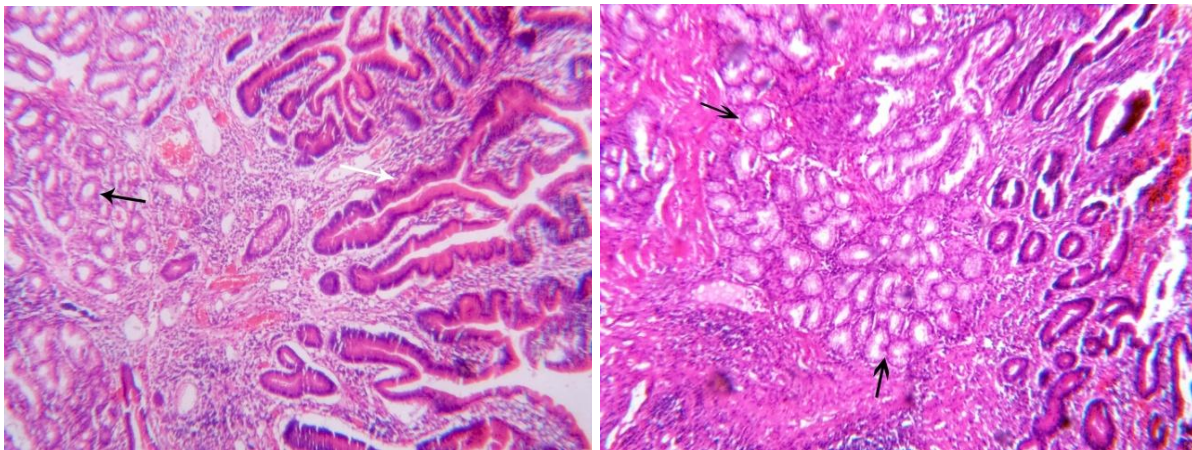
1. Michael E.C. Mcfarlane. Villous tumour of the duodenum: report of a case and review of the literature. *J hepatobiliary pancreat surg* (2001) 8:107–109.
2. Galandiuk S, Hermann RE, Jagelman DG, Fazio VW, Sivak MV. Villous tumors of the duodenum. *Ann surg* 1988; 207: 234-9.
3. Ji Hoon Kim, Jung Woo Choi, Yeon Seok Seo, Beom Jae Lee, Jong Eun Yeon, Jae Seon Kim et al. Inverted cystic tubulovillous adenoma involving Brunner's glands of duodenum. *World J Gastroenterol* 2007 June 21; 13(23): 3262-3264
4. Dupont-Lampert V, Landmann J. Tubulovillous adenoma of the duodenum: case report and review of the literature. *Schweiz Med Wochenschr.* 1989 Jul 29; 119(30):1057-9
5. Charles W. Chappuis, M.D., Frank C. Divincenti, M.D. and Isidore Cohn, jr., M.D. villous tumours of the duodenum. *Annals of surgery*; 207:1989: 593-598.
6. Perry EC. Papilloma of the duodenum. *Trans Pathol Soc (London)* 1893; 44:84-88.
7. Sabahattin Aslan, Bahadır Çetin, Fatma Markoç, Abdullah Çetin. A duodenal villous adenoma associated with in situ carcinoma: A case report. *Turkish Journal of Cancer* 2001; 31(4):162-167.



**Fig.1. Endoscopic view at the level of pylorus showing polypoid tumor (black arrow) in the first part of duodenum**



**Fig.2. Microphotograph showing frond-like mucosal villi (black arrows) with branching papillary structure growing towards the lumen. (H & E Section,  $\times 100$ )**



**Fig.3. Microphotograph showing mucosa with tubulo-villous glands (white arrow) and Brunner's glands (black arrows) extending deep into sub mucosa. (H & E Section,  $\times 100$ )**