IJCRR
Vol 05 issue 19
Section: Healthcare
Category: Research
Received on: 20/08/13
Revised on: 15/09/13
Accepted on: 13/10/13

SUPERNUMERARY RENAL ARTERIES

Flossie Jayakaran, Sayee Rajangam

International Medical School, New BEL Road, MSR Nagar, Bangalore, Karnataka, India

E-mail of Corresponding Author: fjayakaran@yahoo.co.in

ABSTRACT

Renal arteries show a range of variations in origin and distribution to the kidney, with variable distributions and caliber of the vessels on each side. As these have serious implications in transplant surgery and renal imaging, it is imperative to examine the variations possible and also to have a common nomenclature for the variations seen. Standard textbooks note that variations are seen in about 30% of the population with a range of 9-76%[1] and hence it was deemed necessary to add to the existing knowledge of variations in the patterns of the renal artery. 3 kidneys with variable arterial supplies have been described and the variations have been discussed here. A review of literature also showed that the nomenclature of the arteries varied from one study to another. An attempt has been made here to rationalize the terminology for ease of discussion and comparison.

Keywords: Supernumerary arteries, polar arteries, renal segmental arteries, lateral splanchnic arteries

INTRODUCTION

Variations in renal vessels are expected, especially as the incidence of variation has been reported as 9-76%[1]. Variations are gaining greater importance due to MR angiography and transplantation of kidneys from live donors. Standard textbooks comment that while 70% of kidneys show a single artery, 30% of kidneys show supernumerary vessels[2]. This assumes importance for interpretation of radiological material, transplantation and in preventing erroneous interpretation of pyelogram among other serious consequences. Perusal of literature on the topic showed that a number of workers have reported variations of arterial patterns as well as variations in nomenclature of these arteries, using terms such as additional /anomalous /accessory /abnormal /aberrant arteries. The presence of kidneys with variable blood vessels, among the anatomy prosection specimens in the Department, triggered a review of literature and a study to investigate possible patterns of renal vessels.

MATERIAL AND METHODS

3 isolated kidneys, 1 right and 2 left kidney, which were used for student prosection showed renal vessels that could be termed 'anomalous/aberrant/accessory'.

The 3 kidneys that made up this material were a pair of kidneys (1a and 1b) with an intact segment of the abdominal aorta and a segment of the inferior vena cava (Fig 1 and 2). The next specimen was an isolated left kidney with its vessels intact but not connected to an aorta or inferior vena cava (Fig 2). The specimens were photographed after clearing the connective tissue around the hilum and investigating the extra-hilar course of the arteries that supplied each kidney. The kidneys and the arteries entering it were not subjected to any further dissection.

RESULTS

Kidney 1a (Fig.1) was supplied mainly by the right renal artery which divided 2.5 cm from the

aorta into 4 segmental branches before reaching the hilum of the right kidney (Fig.1: 1-4). 3 of these branches were anterior branches, (Fig.1: 1-3), and entered the hilum anterior to the pelvis of the ureter. One (Fig.1: 4) traveled behind the pelvis of the ureter to enter the hilum. An additional artery (Fig. 1: 5) arose from the aorta 2 cm above the right renal artery and entered the kidney at the upper end of the hilum, posterior to the upper part of the pelvis of the ureter.

Kidney 1b (Fig.2) was supplied by the left renal artery, which branched outside the hilum into 2 branches. Each of the 2 branches divided again into 2 arteries, but at varying distances from the hilum. All 4 branches entered the hilum behind the right renal vein and in front of the pelvis of the ureter. (Fig. 2: 3-6). 3 additional arteries branched from the aorta to supply the left kidney: two above and one below the left renal artery. The highest one (Fig. 2: 1) pierced the medial border of the kidney 0.5 cm above the hilum. The second one (Fig 2: 2) entered the upper part of the hilum behind the renal pelvis. The third additional artery (fig 2: 7) entered the kidney at the lower part of the hilum behind the renal pelvis. Altogether 7 arterial branches were noted.

Kidney 2 was an isolated left specimen. A single left renal artery divided before the hilum into 2 branches. The upper branch of the renal artery (Fig. 3: 1) after giving off a branch (presumably to the left suprarenal gland) pierced the anterior surface of the kidney below the upper pole. The lower branch (Fig.3:2) divided into 3 arteries (Fig 3: 2a, 2b, 2c), 2 of which, (2a and 2b), entered the hilum at the middle and lower end of the hilum respectively, while the last branch, (2c), given off posteriorly, entered the middle of the hilum behind the pelvis of the ureter.

DISCUSSION

Standard text books of Anatomy describe a pair of renal arteries that arise from the abdominal aorta at the level of the vertebral disc between L1 and L2. Each artery divides into 5 segmental arteries (superior, antero-superior, antero-inferior, inferior and posterior) that supply the 5 segments of the kidney[3]. The right artery is longer, often higher and runs behind the Inferior Vena cava (IVC) and behind the right renal vein. The left renal artery is slightly lower, behind the corresponding vein and crossed by the Inferior Mesenteric Vein. In 70% of cases, one artery branches to supply each kidney[2]. These arteries show variability of caliber, in the degree of obliquity and the precise relations.

The kidneys in this report had normal renal arteries as described in standard text books. They also had additional arteries arising from the aorta, above and below the renal artery (Kidney 1A & B). Kidney 1a had 4 arteries from the renal artery which entered the hilum to possibly supply 4 vascular renal segments, with the supernumerary artery (5) directly from the aorta (Fig.1: 1a:5) supplying the 5th vascular segment. Since no dissection was done this could be an informed comment on its area of supply. 5 vascular renal segments have been described in textbooks for each kidney[2].

Kidney 1b had 7 branches supplying the left kidney of which one pierced the surface outside the hilum of the left kidney and could be called a polar artery[2] (Fig 2: 1). The 6 vessels that entered the left hilum included the 4 branches of the left renal artery proper (Fig 2: 3-6) and 2 accessory vessels[2] from the aorta (2 & 7) that may be supplying the posterior vascular segment. These (1, 2 and 7) would be the persistent lateral splanchnic arteries that supply the kidney as it ascends out of the pelvis during development[2], though Hlaing et al[8] reported this phenomenon as pertaining to arteries that supply the lower pole only.

Kidney 2 had a normal left renal artery from the aorta. However, the segmental branch to the upper pole was not through the hilum as is normally seen, but piercing the anterior surface of the upper pole and could be called Upper polar artery[1] or

Superior renal polar artery[2]. Polar arteries have been described as arising from anomalous/accessory arteries [6] or from the renal artery proper[2]. In this study, the artery supplying the upper pole in Kidney 2 arose from the normal left renal artery. 3 segmental branches of the left renal artery were seen entering the hilum instead of the expected 4 arteries. The possibility remains that further branching of the artery may occur within the kidney parenchyma.

Supernumerary arteries are relatively common (an incidence of 30%[2]), and had raised concerns that their narrow calibers may contribute to renal ischemia and increase the risk of hypertension – an event which has since been reported to show no statistical significance[5]. These arteries represent persistent embryonic lateral splanchnic arteries which grow in sequence from the aorta to supply the kidney as it ascends from the pelvis[4]. These arteries may arise from the aorta, coeliac trunk, superior mesenteric artery, inferior mesenteric artery and the aorta near its bifurcation[2]. Often called accessory renal arteries, the supernumerary arteries to the lower pole may be clinically important as they may obstruct the pelvi-ureteric junction resulting in hydronephrosis.

Supernumerary arteries are reported to be present in 30% of kidneys[2], though other reports mention 40%[6], 24%[5], 20%[7] and 4%[8]. It is reported to be more commonly seen on the left side[1] where they enter the lower pole[7.] In kidney 2 of this report, there are 3 additional arteries to the left kidney, one of which pierces the anterior surface and 2 which enter through the hilum.

Variations in the renal arteries have serious consequences for surgeons and radiologists as has been elaborated in several reports[1, 5-8]. Consistency of nomenclature therefore is required in the description of variations. It is suggested that the following nomenclature for supernumerary arteries may be used to reduce confusion.

i) Hilar arteries enter the kidney at the hilum irrespective of their origin.

ii) Extrahilar do not enter the kidney through the hilum and irrespective of their origin, may be called (a)'perforating' if it perforates any surface of the kidney, or (b) 'polar', if it supplies the upper and/or lower poles[7]. Kidneys 1b and 2 may therefore be said to have a perforating polar artery each to the upper poles of the respective kidneys. Saritha et al called the extrahilar arteries as 'accessory' vessels, distinguishing polar accessory vessels from hilar accessory vessels.

Terms such as aberrant, abnormal & anomalous do not convey precise information and may therefore be unsuitable in a scientific context, as each artery, whether it arises from the aorta or other vessels, does supply a specific segment of the kidney. All segmental arteries are end arteries supplying a resectable unit/renal segment and do not show significant anastomosis with other vessels. They are therefore not aberrant, abnormal or anomalous[1].

CONCLUSION

The present study has reported the presence of additional branches to the kidneys from the abdominal aorta and the renal artery. These variations in the organization of neurovascular structures at the renal hilum will provide valuable information to surgeons and radiologists before procedures are undertaken. A scheme for nomenclature of supernumerary vessels has also been suggested in this report.

REFERENCES

1. Talovic E, Kulenovic A, Voljevica A, Kapur E. Review of Supernumerary Renal Arteries by Dissection Method. Acta Medica Academica 2007; 36: 59-69
2. Standring S, (ed) Gray's Anatomy 40th ed. 2008. Churchill Livingstone Elsevier, UK
3. Moore KL, Dalley AF, Agur AMR. Clinically Oriented Anatomy. 6th ed. 2010 Lippincott Williams & Wilkins, India

4. Snell R S. Clinical Anatomy by Regions. 8th ed. 2008 Lippincott Williams & Wilkins, USA.
5. Gupta A, Tello R. Accessory Renal Arteries Are Not Related to Hypertension Risk: A Review of MR Angiography Data. Am J of Roentgenology 2004; 182: 1521-1524
6. Madhyastha S, Suresh R, Rao R. Multiple Variations of Renal Vessels. Indian J of Urology: Case Report 2001; 17 (2):164-65
7. Saritha S, Jyothi N, Praveen Kumar M, Supriya G. Cadaveric Study of Accessory Renal Arteries and its Surgical Correlation. Int J Res Med Sci 2013; 1 (1): 19-22
8. Hlaine KPP, Das S, Sulaiman IM, Latiff AA, Ghafar NA, Suhaimi FH, Othman F. Accessory Renal Vessels at the Upper and Lower Pole of the Kidney: A Cadaveric Study with Clinical Implications. Bratisl Lek Listy 2010; 111(5): 308-10

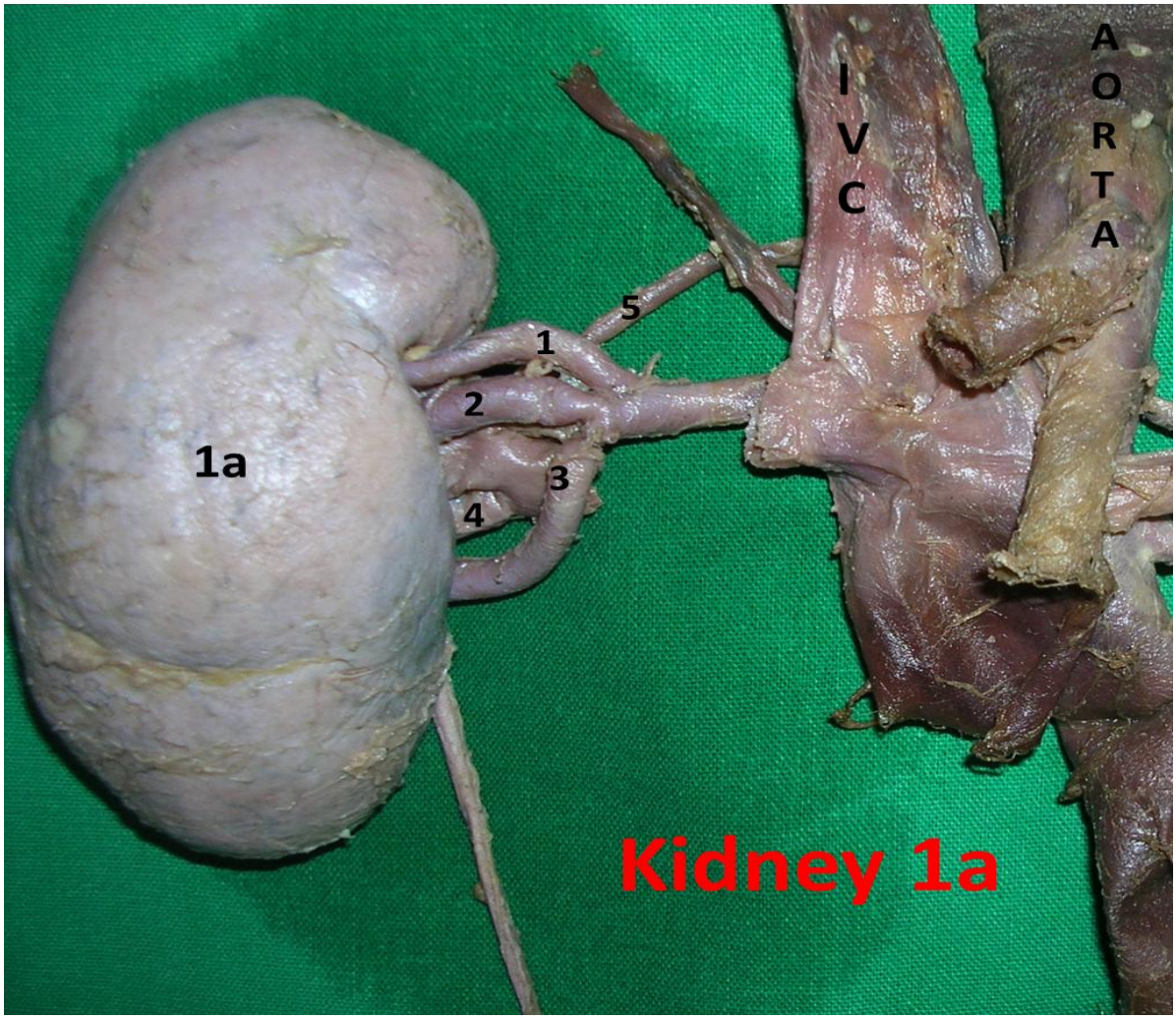

Fig1. Right kidney 1a: Right renal artery with its 4 branches to the hilum (1-4), and the hilar artery (5) from the abdominal aorta, (IVC= Inferior Vena cava)

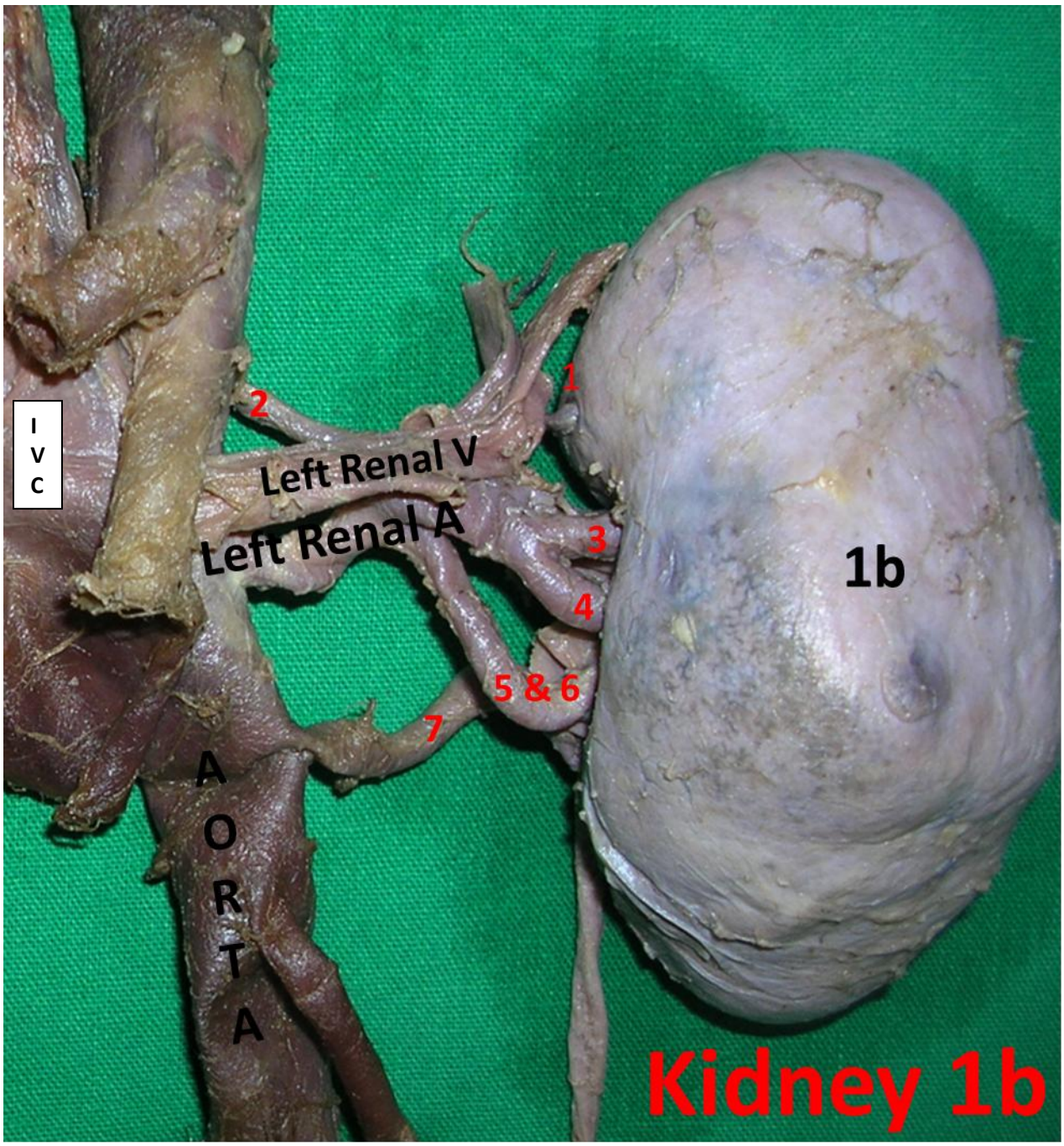

Fig. 2: Left Kidney 1b: IVC – Inferior venacava, 3-6 = Branches of the renal artery, 1, 2 & 7= supernumerary arteries from the aorta

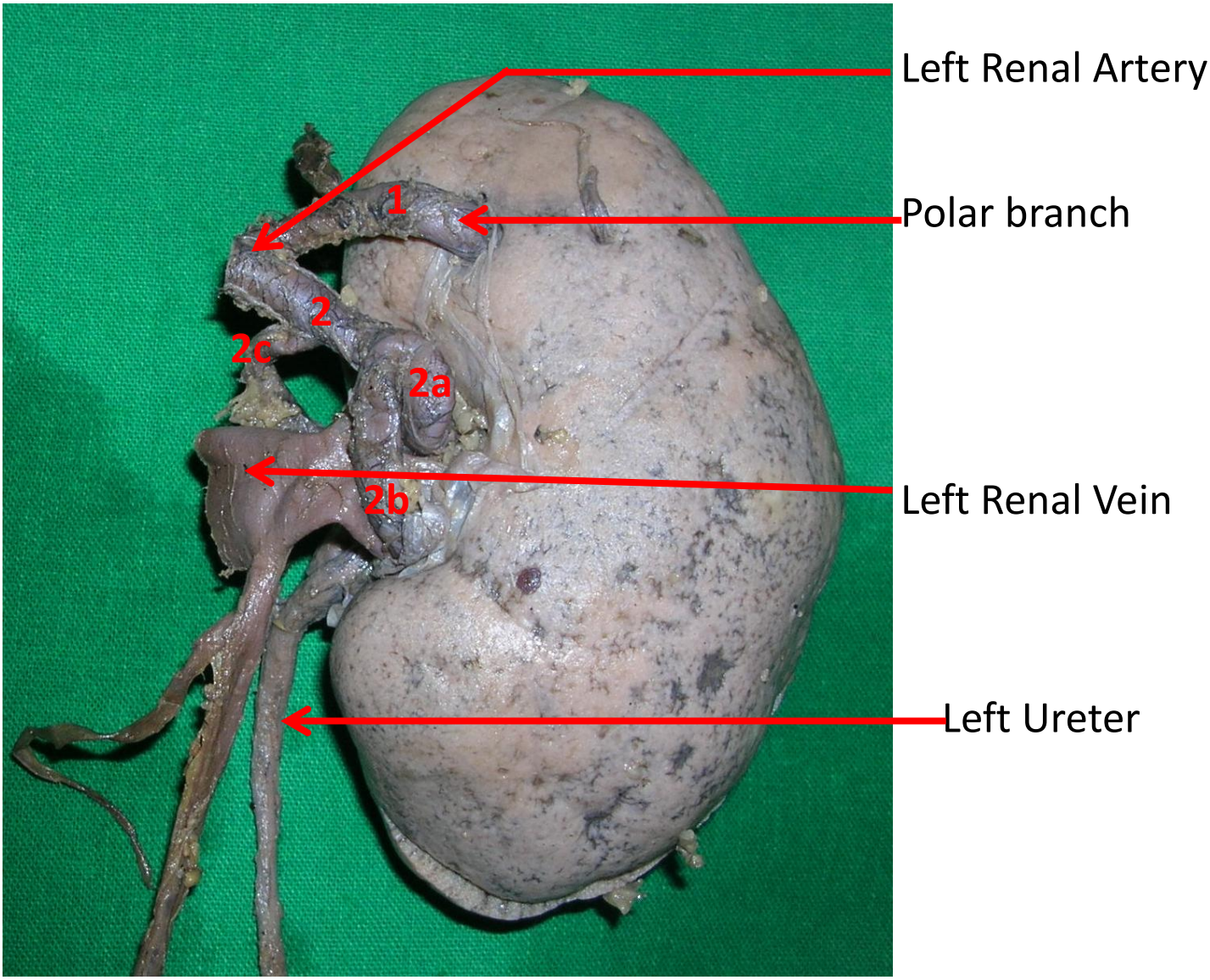

Fig. 3 – Kidney 2- 1, 2, 2a, 2b, 2c = branches of the left renal artery